



The University of Texas
Health Science Center at Houston

School of Dentistry



**Oral Health: Within Age-friendly Health
System & The 4Ms Framework**

Oral Health Within Age-friendly Health
System At BRIDGE, NY.

September 27, 2021

A solid orange horizontal bar at the bottom of the slide.

Disclaimer

The opinions expressed in this presentation are those of the speaker and not necessarily those of UTHealth School of Dentistry at Houston.

“This presentation was made possible by Grant Number K01HP33459 from the Health Resources and Services Administration (HRSA), an operating division of the U.S. Department of Health and Human Services. Its contents are solely the responsibility of the authors and do not necessarily represent the official views of the Health Resources and Services Administration or the U.S. Department of Health and Human Services.”

The opinions expressed in this course should not be construed as advice to care for specific patients

Neither I, nor members of my immediate family have any financial relationship with commercial entities that may be relevant to this presentation.

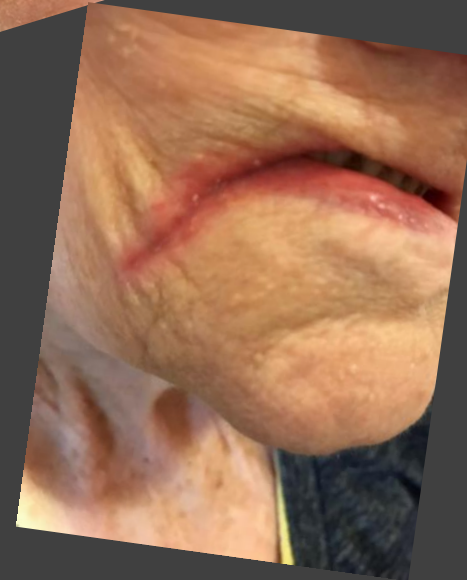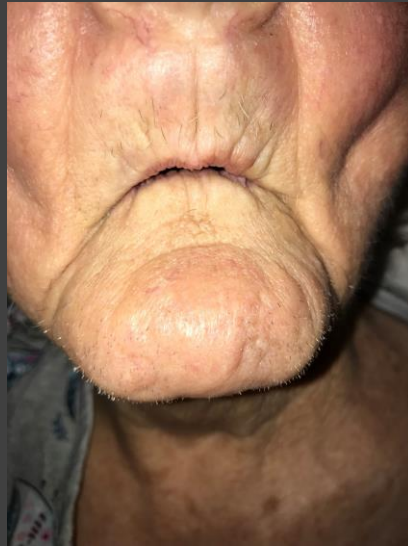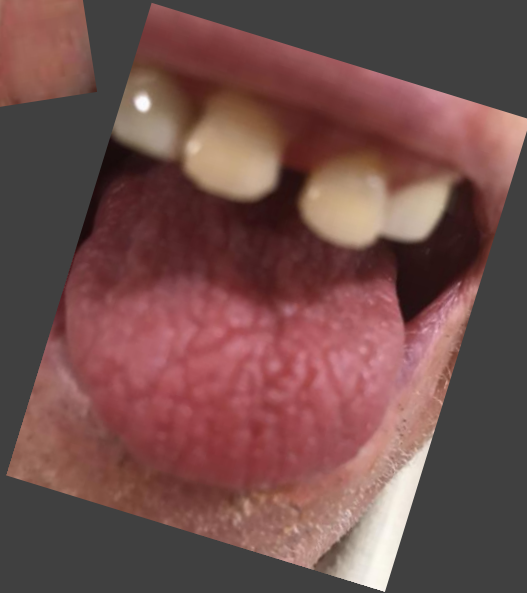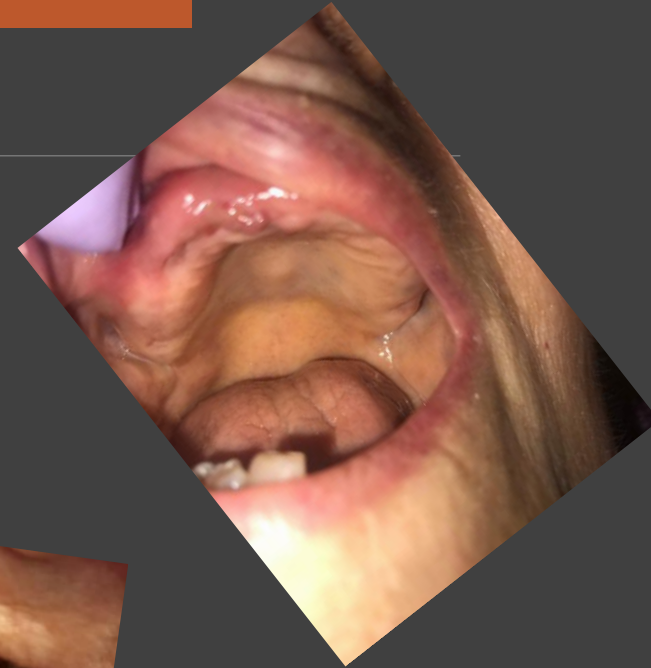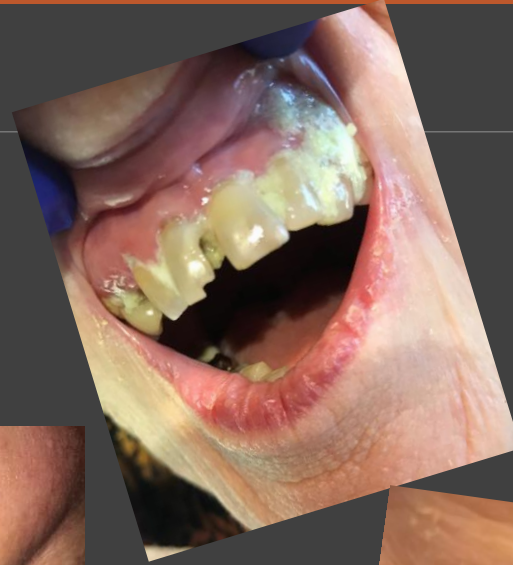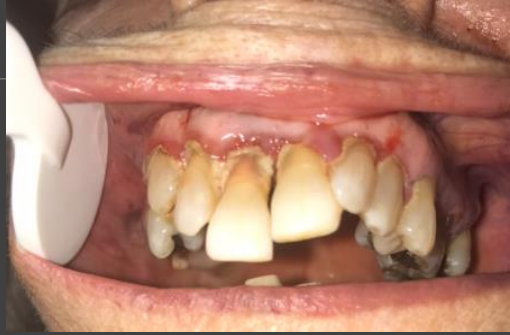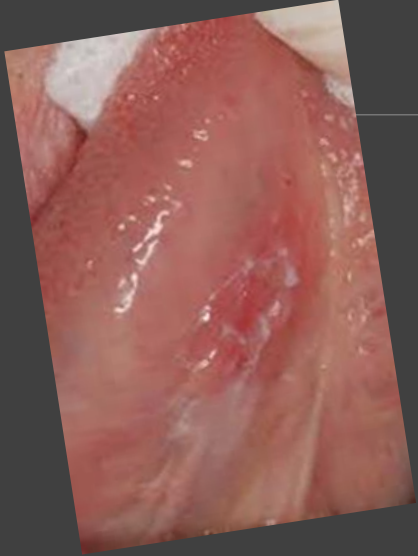Objectives

- Intergrade the oral health within the 4Ms/
- Providing oral assessment during collecting the 4Ms baselines/ and
- Recognize the oral abnormalities

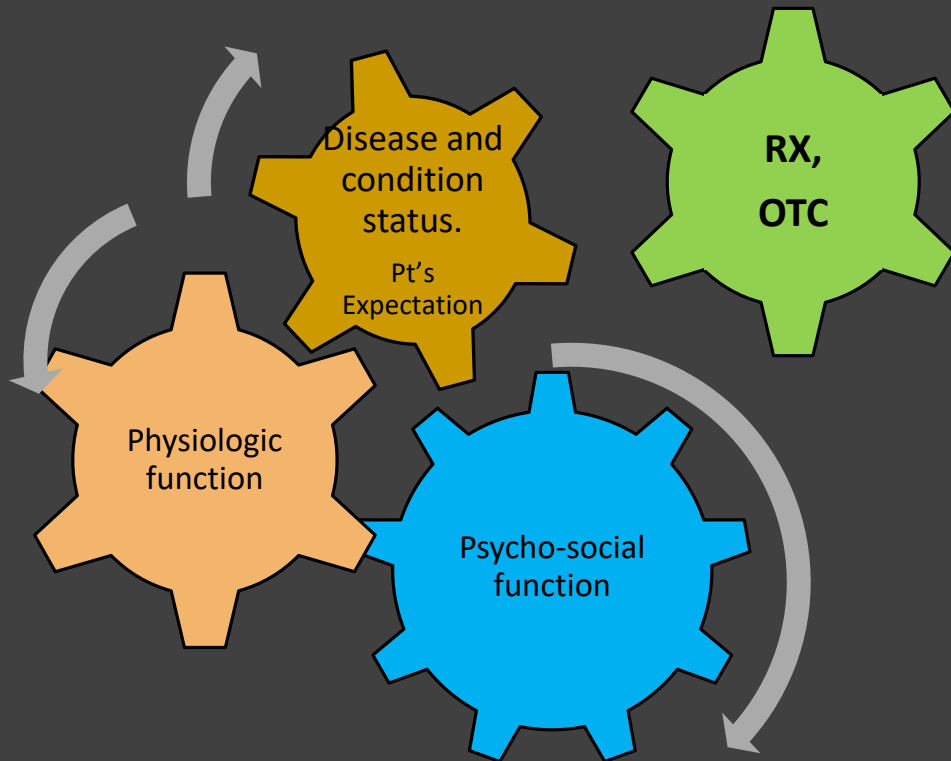
Poll #1

Do you think oral health education is sufficiently taught in all health professional disciplines?

Look in the Mouth

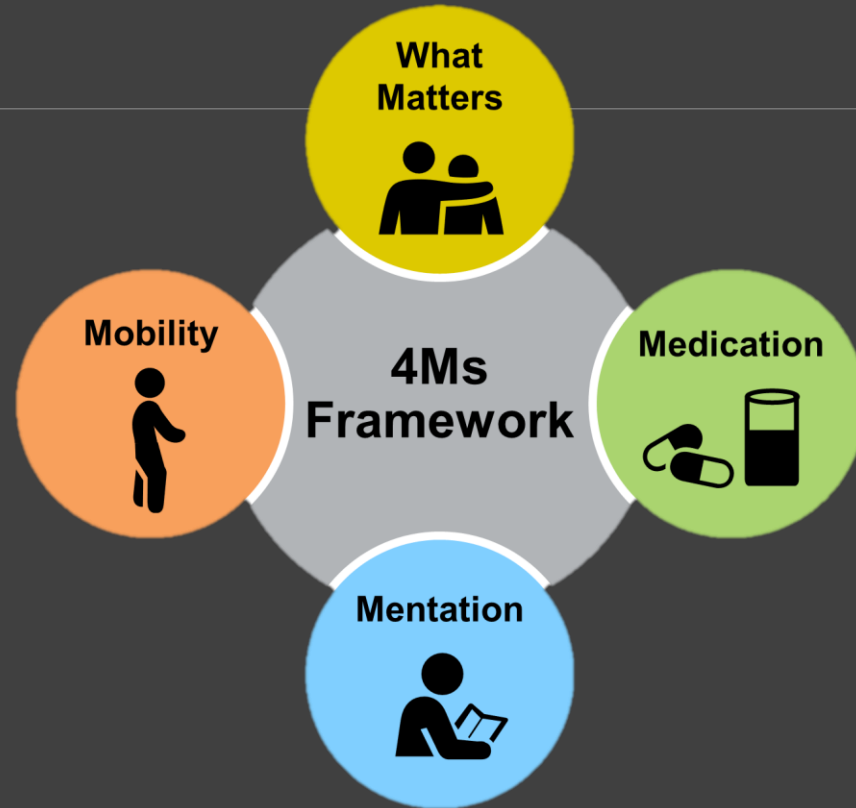


The 4Ms of the Geriatric Oral Health



Oral health is multi-faceted and includes the ability to speak, smile, smell, taste, touch, chew, swallow and convey a range of emotions through facial expressions with confidence and without pain, discomfort and disease of the craniofacial complex.

Glick M, Williams DM, Kleinman DV, Vujicic M, Watt RG, Weyant RJ. A new definition for oral health developed by the FDI World Dental Federation opens the door to a universal definition of oral health. British dental journal. 2016 Dec;221(12):792-3.



What Matters

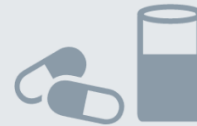

Mobility



4Ms Framework

Medication



Mentation



Mentation Associates With Oral Health

Multiple teeth abscess

Ht. 5'9", Wt. 172

V/S: BP - 147/94, P - 82

His history is significant for Ischemic stroke 3 years ago, he is not communicable. Mild swallowing difficulties. Alzheimer's and depression.

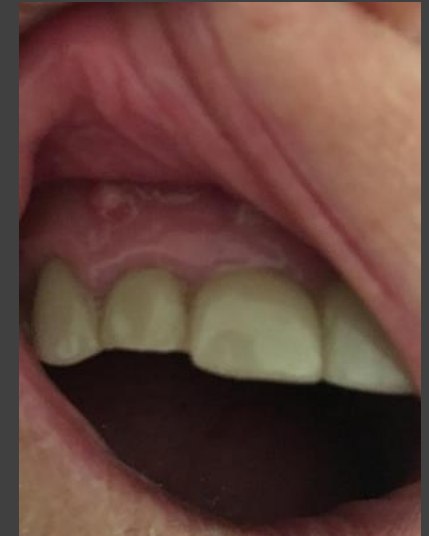
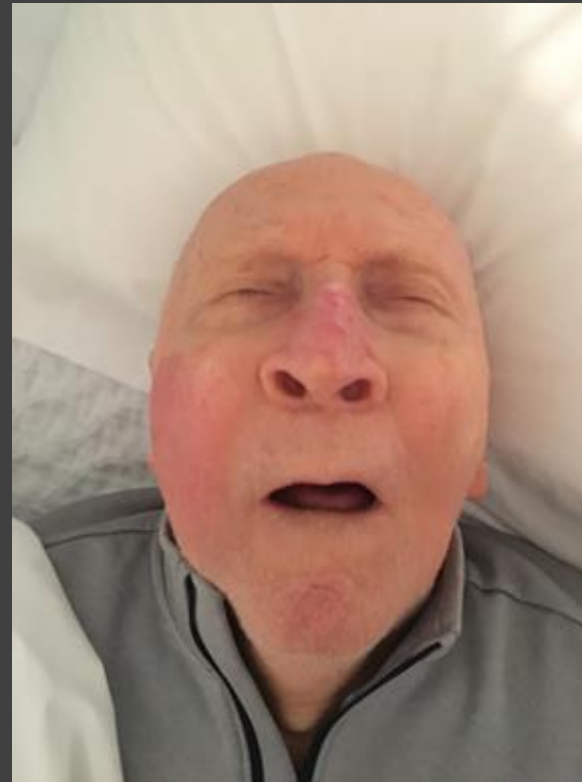Medication:

Sertraline 25 mg for depression
(SSRI)- Zoloft

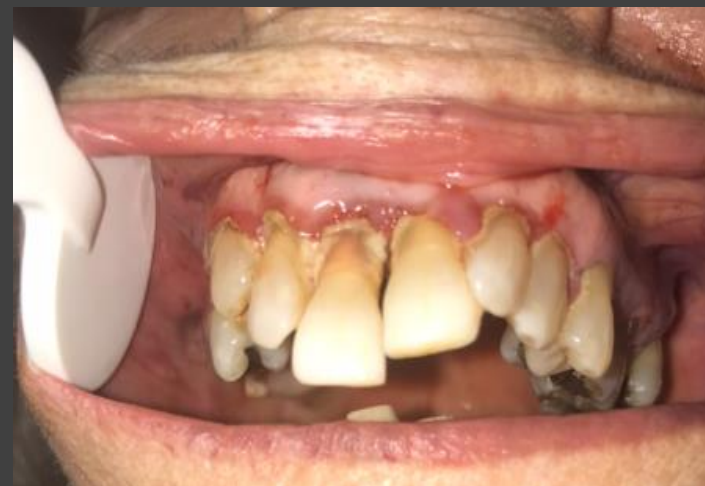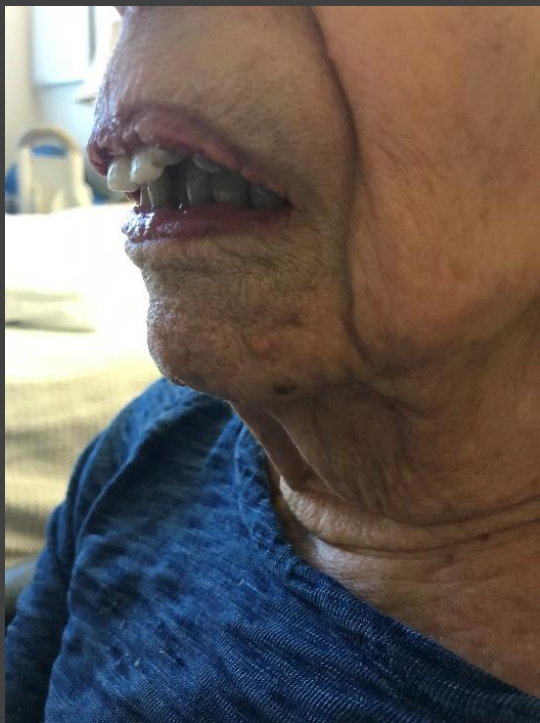Warfarin 7.5mg for Stroke and heart
attack

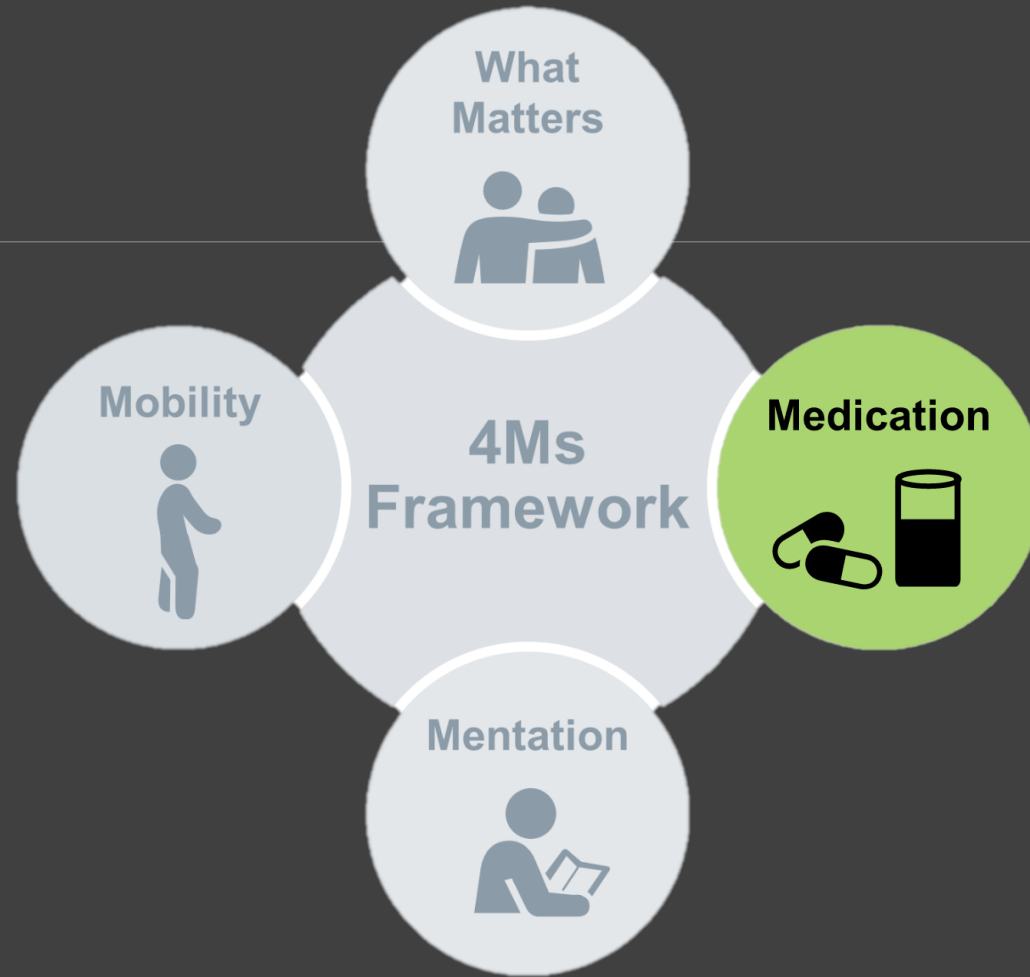
Acetaminophen , As needed (NSAID)
benzodiazepine; Anxiety 0.5 mg x3/
daily- Xanax

Memantine



Nancy has hard time chewing with teeth mobility

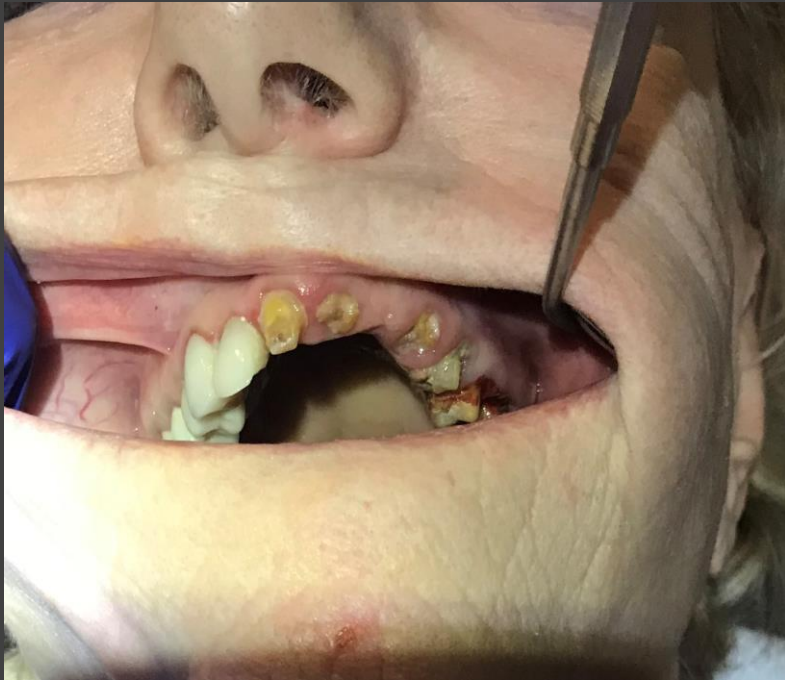



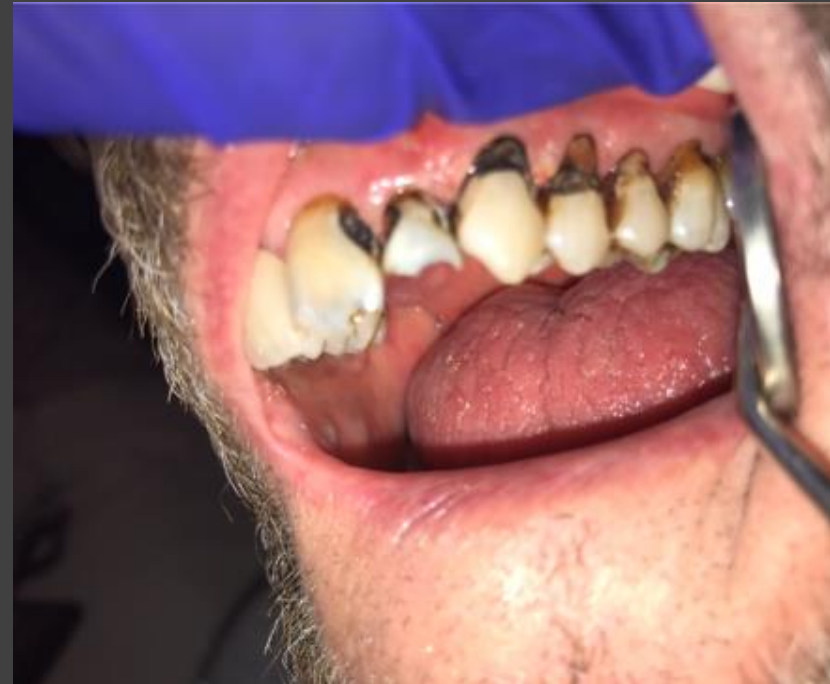CLASS	CONDITION FOR PRESCRIBING	ORAL HEALTH CONCERNS
Antihistamines	Allergies, Flu symptoms	Sedating and strong anti-cholinergic properties
Antispasmodic	IBS/ constipation	Sedating and strong anti-cholinergic properties
Antidepressants	Clinical depression, anxiety, insomnia	Sedating and strong anti-cholinergic properties
Muscle relaxants	MS, stroke, other muscular spasms, fibromyalgia	sedating and strong anti-cholinergic properties
Hypnotics	Panic and sleep disorders, seizures, and agitation	Promotes falls and delirium
Antipsychotic agents	Behavioral management	Increased risk of stroke and death
Opioids analgesics	Moderate to severe pain management	Accumulative effects with other anti-cholinergic drug Risk of abuse
Alpha 1 blocker	BP/ BPH/ LUTS	Dryness, oral candidiasis
Beta blockers	BP	Hyperplasia of the gums
Non-COX selective NSAIDs	Chronic pain	GI bleeding, reduced renal function and blood flow, exacerbation of heart failure

Lost a long span bridge due to
root caries

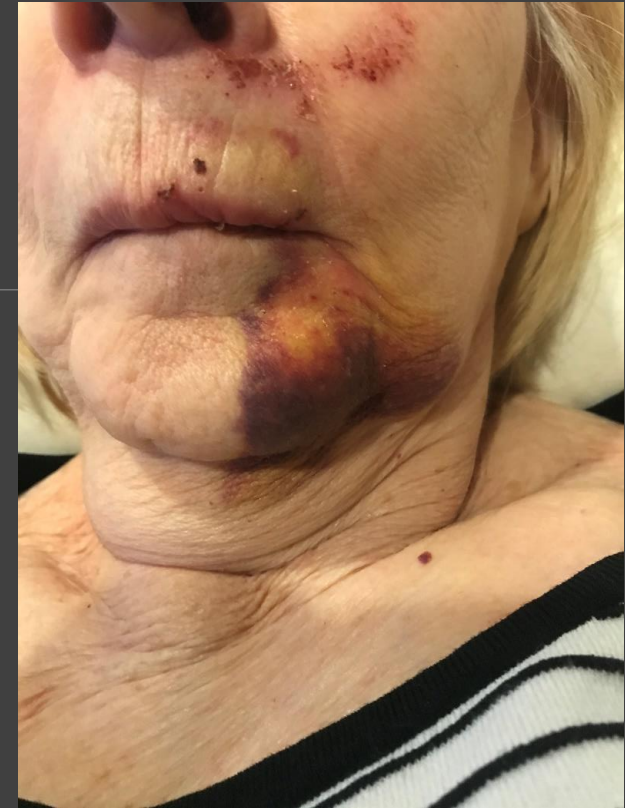
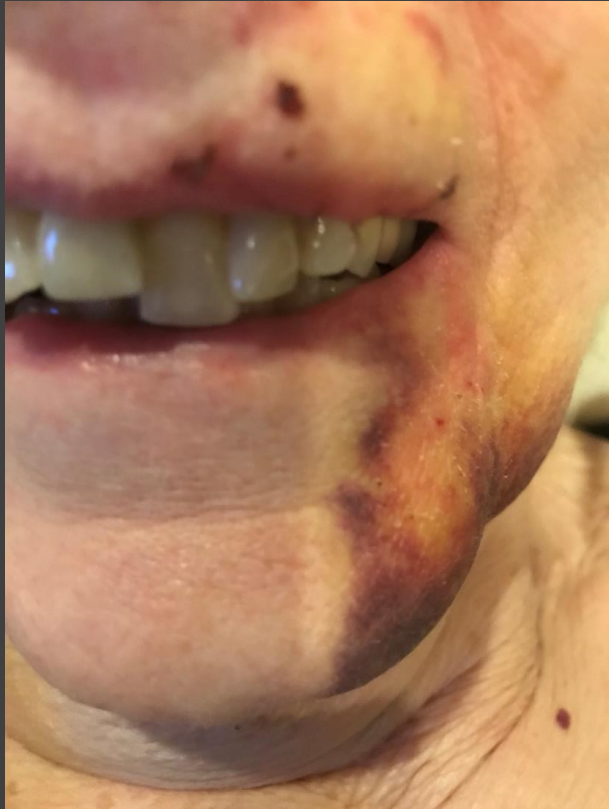Root caries due to xerostomia and
tissue recession.

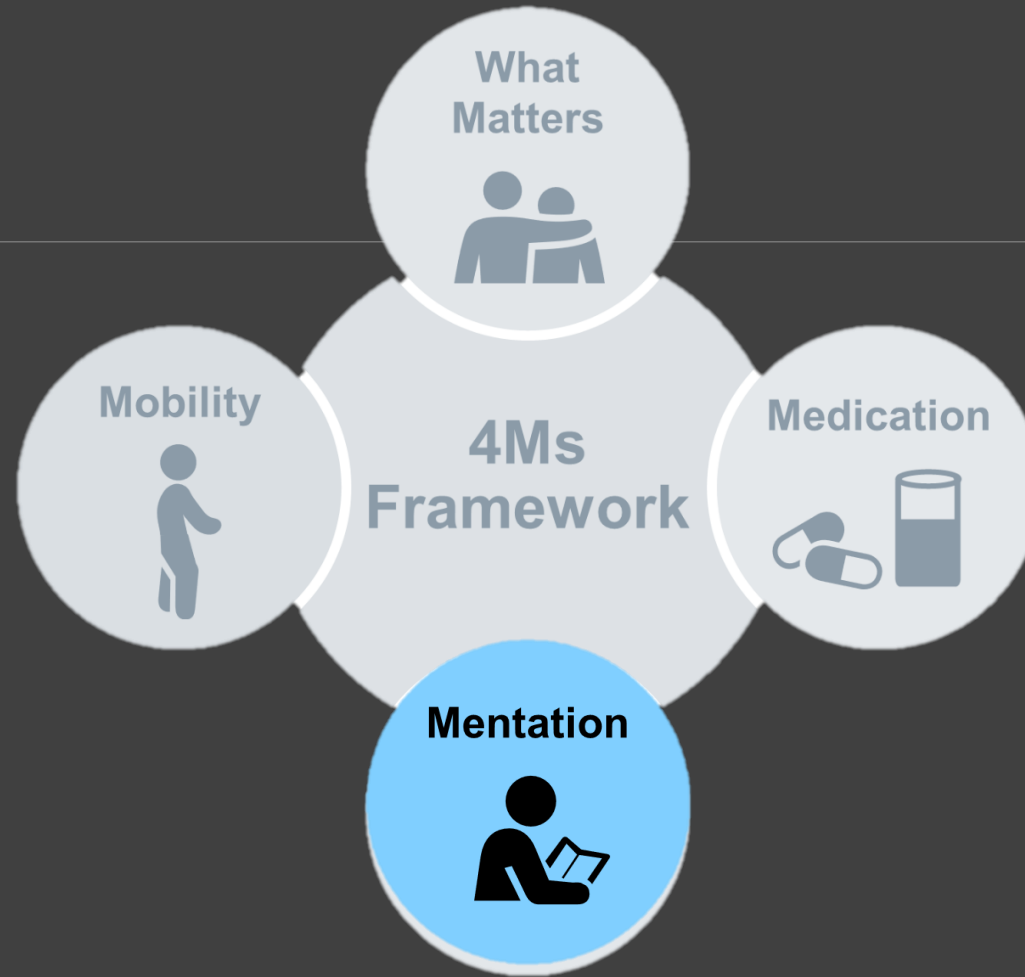


Most Medications
cause Xerostomia
DRY MOUTH



- 1- Antihypertensive
- 2- Diuretics
- 3- B-Blockers
- 4- Sedatives/Hypnotics
- 5- Neuroleptics/Antipsychotics
- 6- Antidepressants
- 7- Benzodiazepines
- 8- NSAIDs

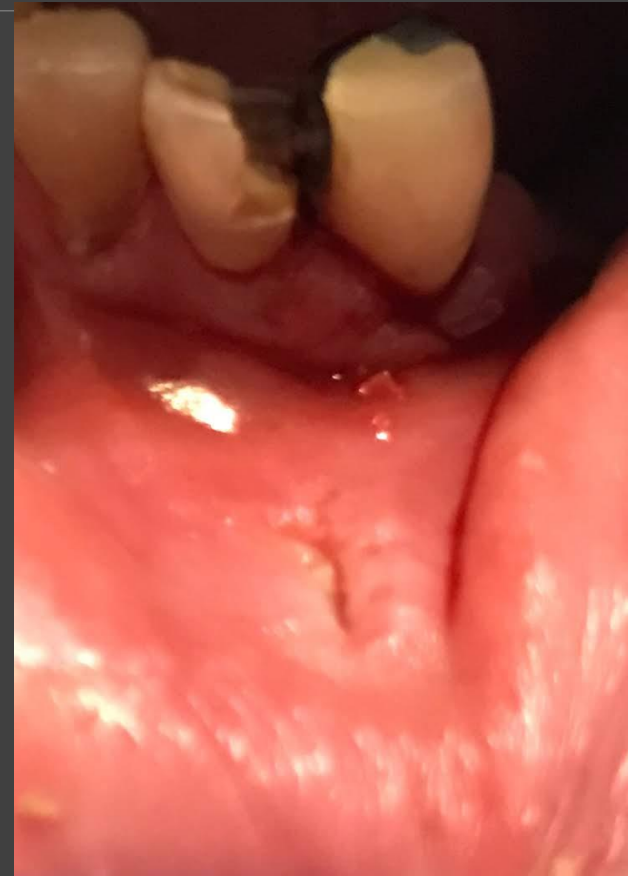
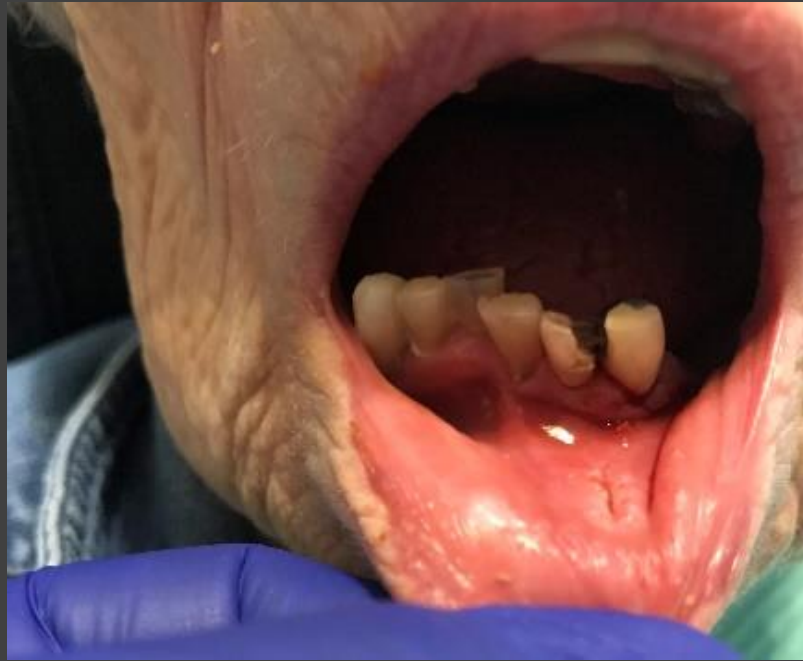




Elderly with **healthy**
cognition proven to have
healthier mouth.

Telehealth



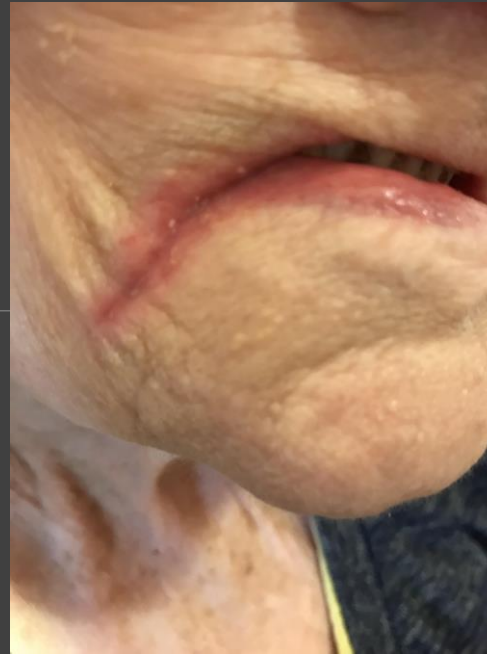Photos by Dr. Tabrizi

Fungus infections may occur by:

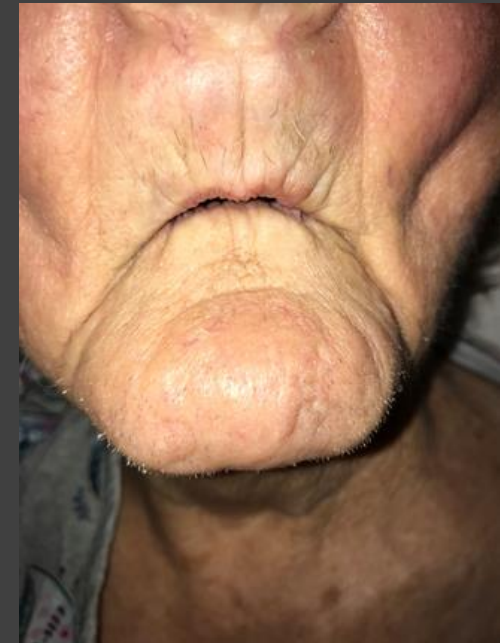- 1 - Ill fitting prostheses
- 2 - Angular colitis

Angular Cheilitis (Treat with antifungals for 2 weeks)

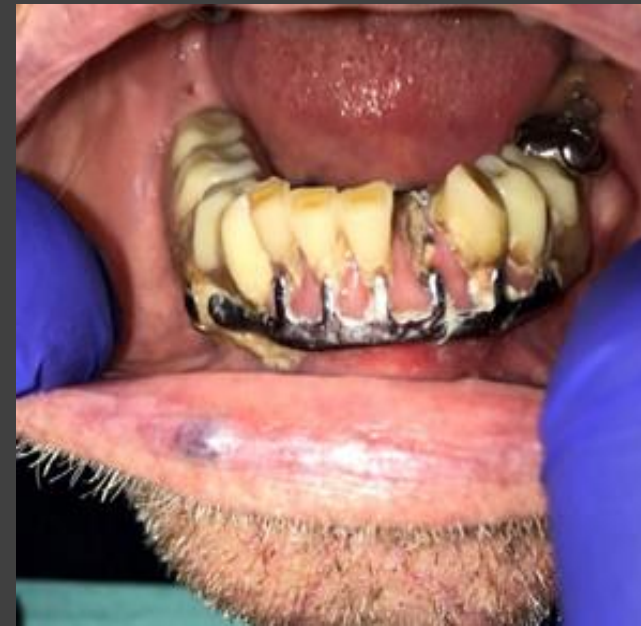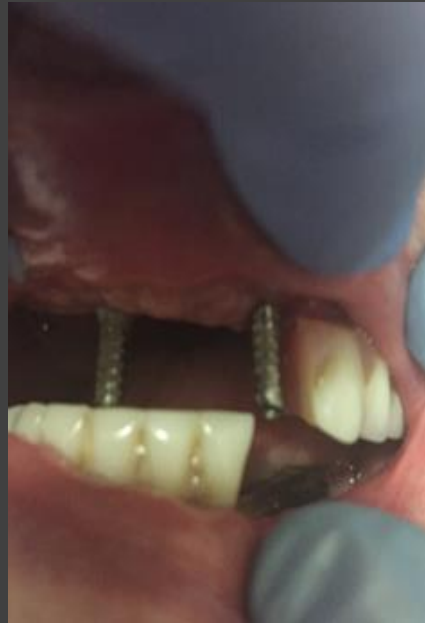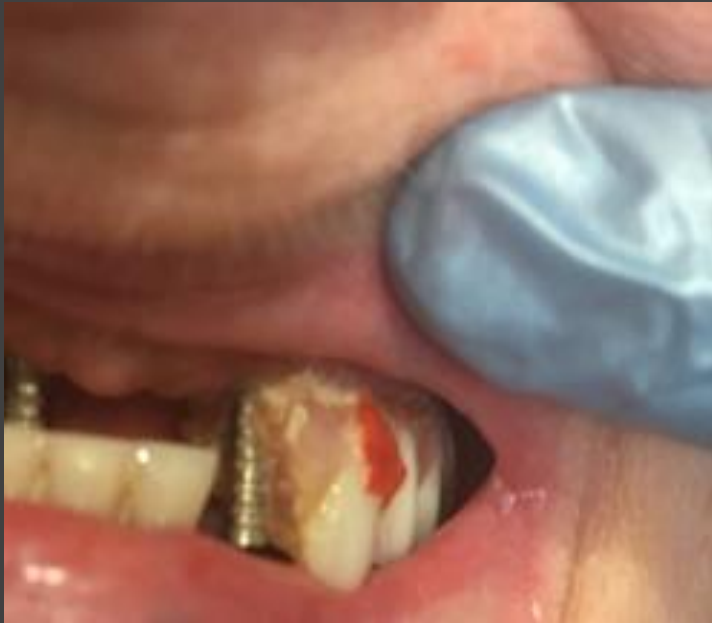Associated with age, complete edentulism, drooling, lack of denture stability, and the presence of oral *Candida Albicans*, staph & streptococci

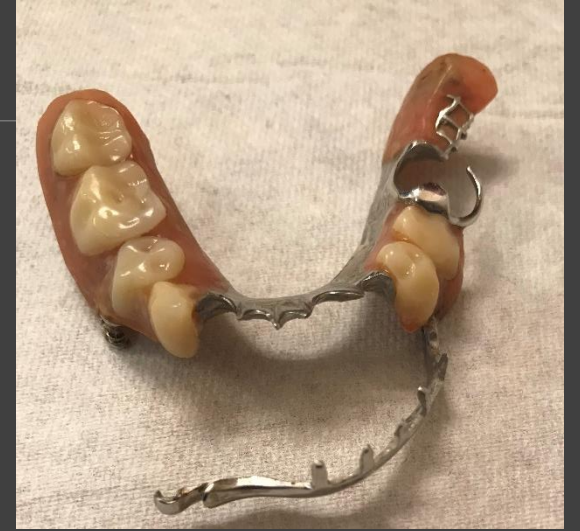
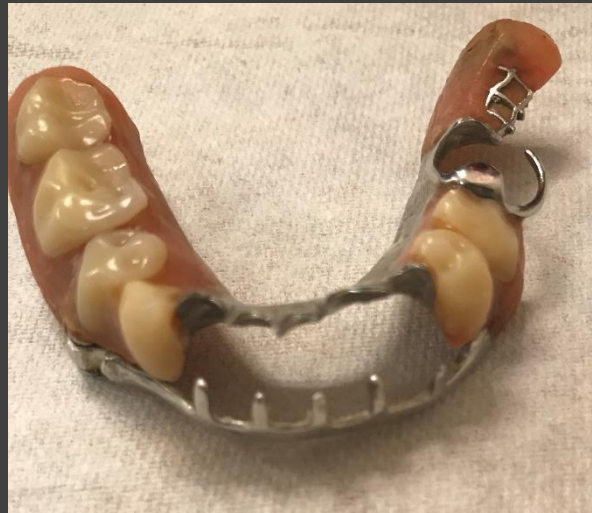
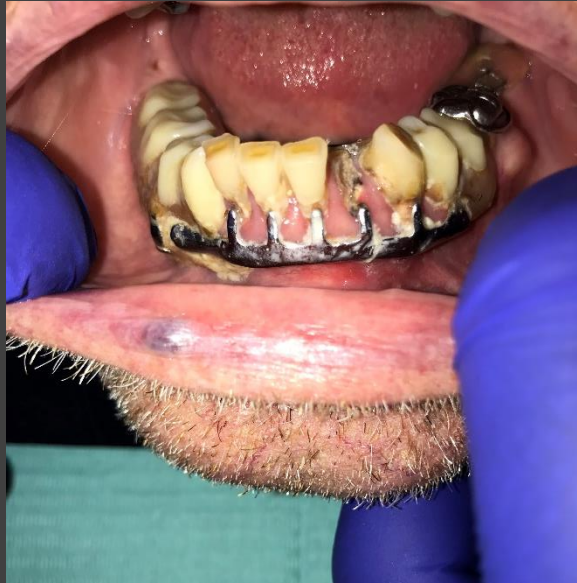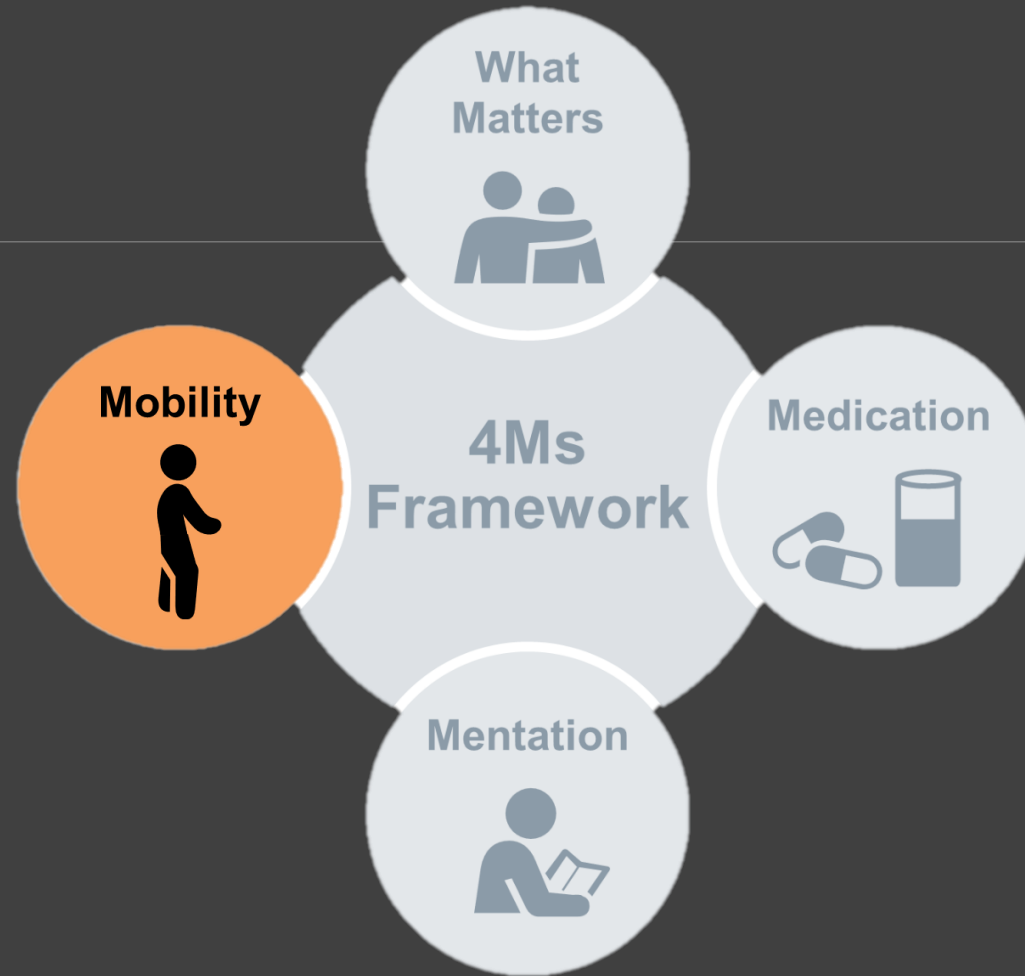
Collapsed of normal
Facial dimension
Profile due to tooth
loss



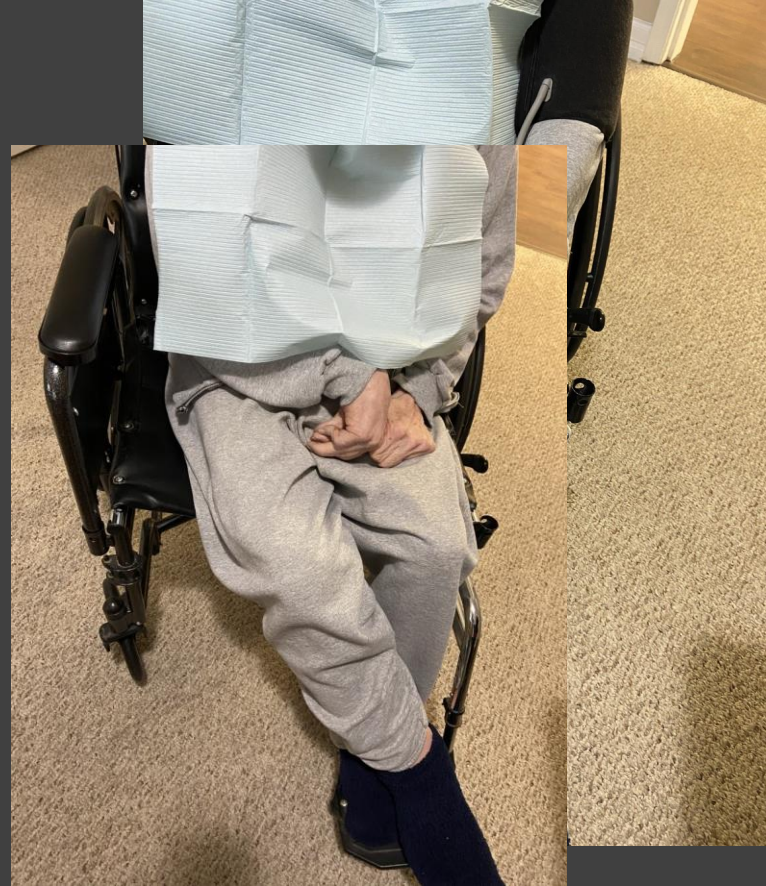Not well maintained removable Oral Prostheses







Mobility, is Associated with Oral Health



Frank is 88

Ht. 5'9", Wt. 172

V/S: BP - 147/94, P - 82

His history is significant for Ischemic stroke 3 years ago, he is not communicable. Mild swallowing difficulties. Alzheimer's and depression.

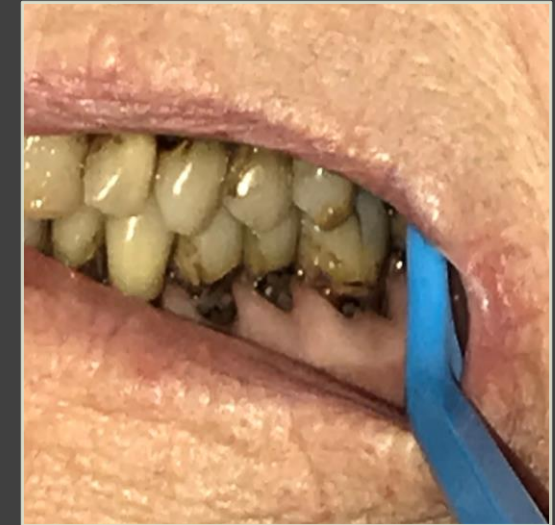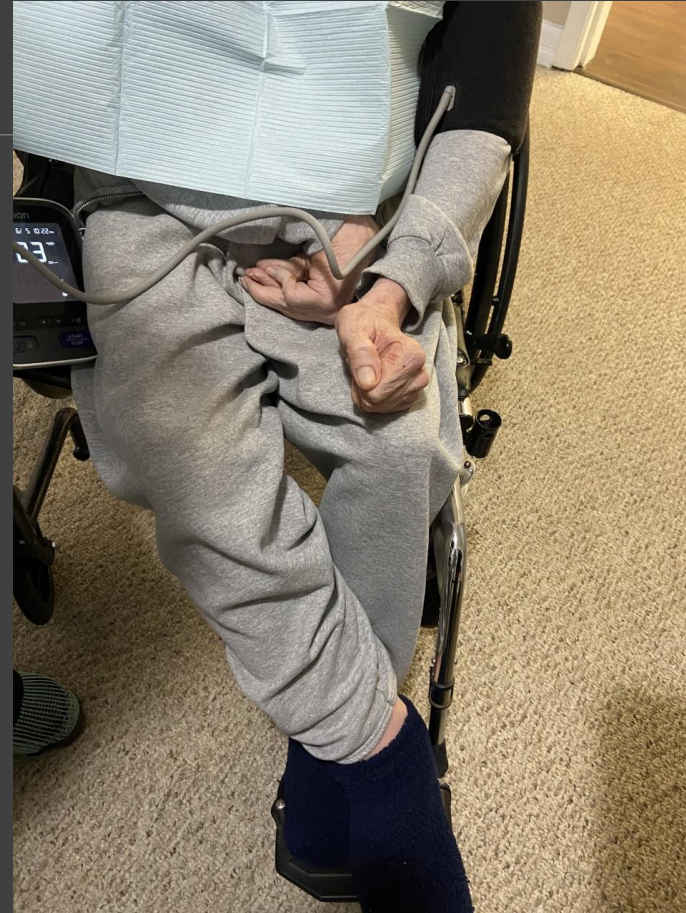Medication:

Sertraline 25 mg for depression (SSRI)-
Zoloft

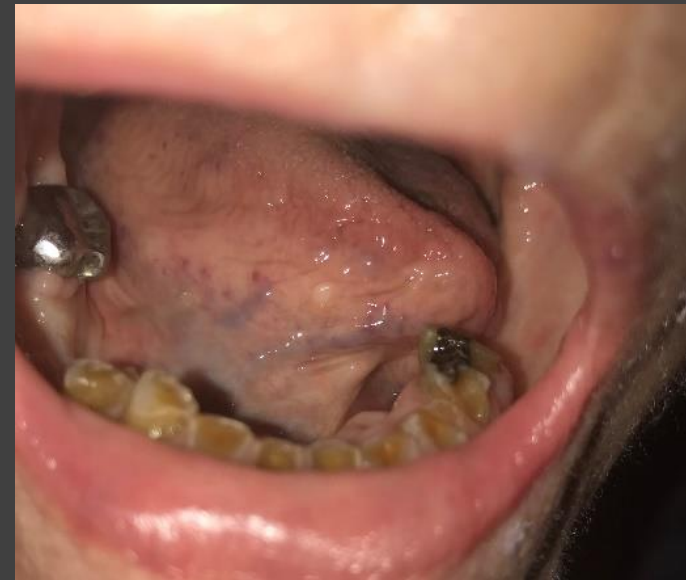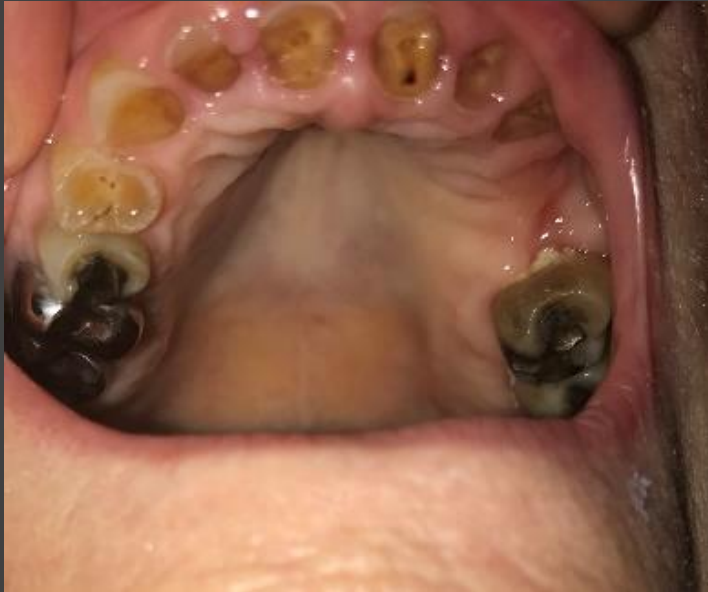Warfarin 7.5mg for Stroke and heart
attack

Acetaminophen , As needed (NSAID)
benzodiazepine; Anxiety 0.5 mg x3/
daily- Xanax

Memantine

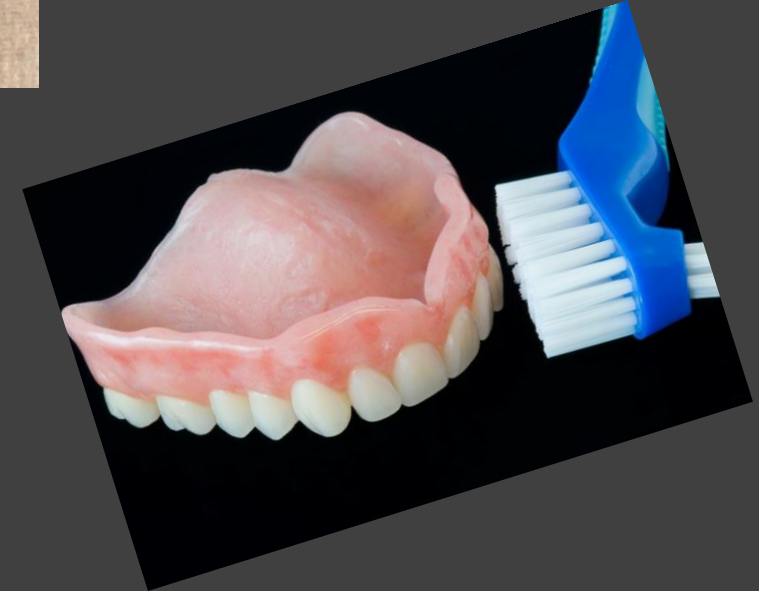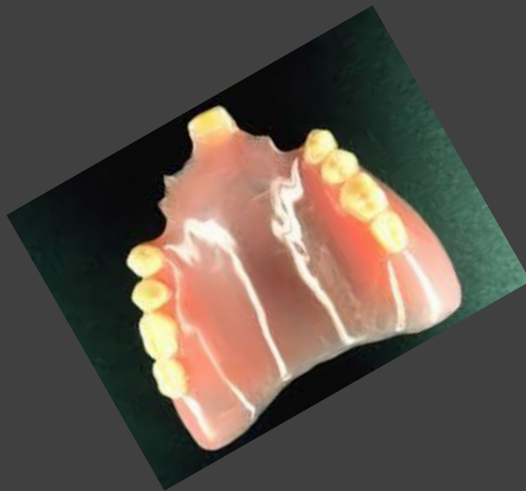

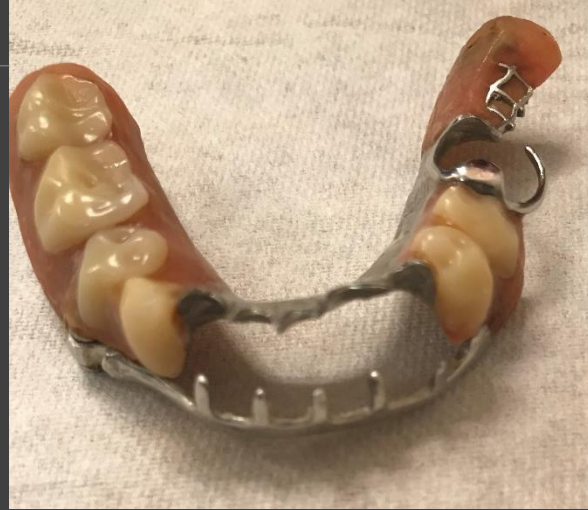
It is all about disease free and functional!



Photos by Dr. Tabrizi

Removable oral prosthesis



Denture Induced Stomatitis (DIS)

*Related with low PH and high sugar consumption,
and poor oral hygiene.*

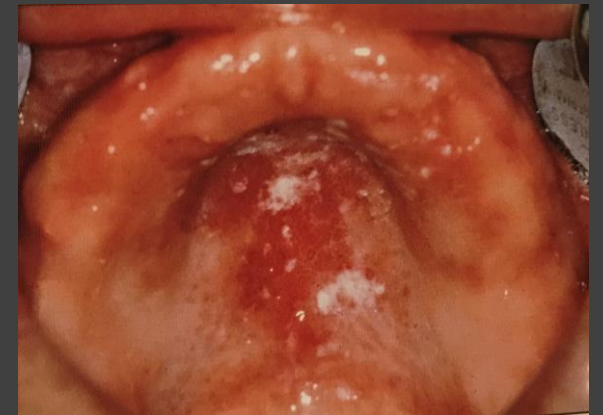
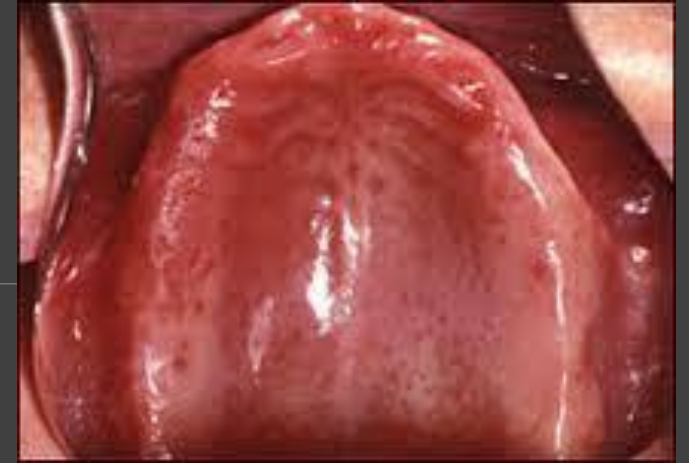
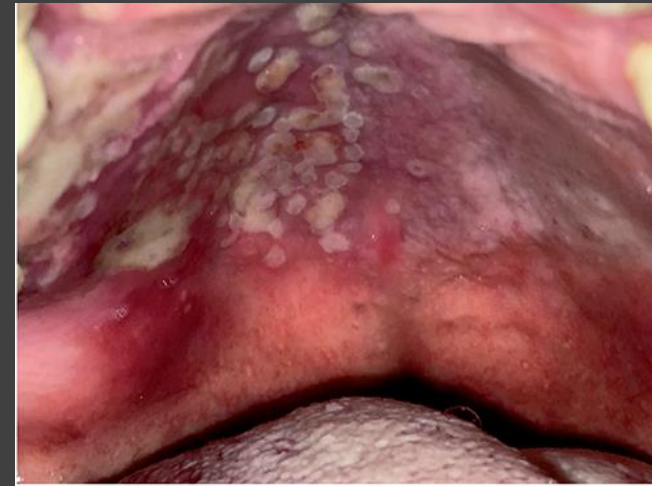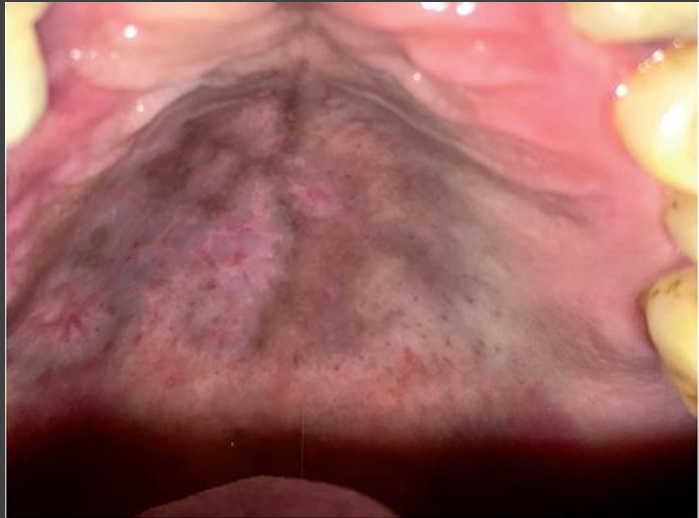Image by Dr. Tabrizi

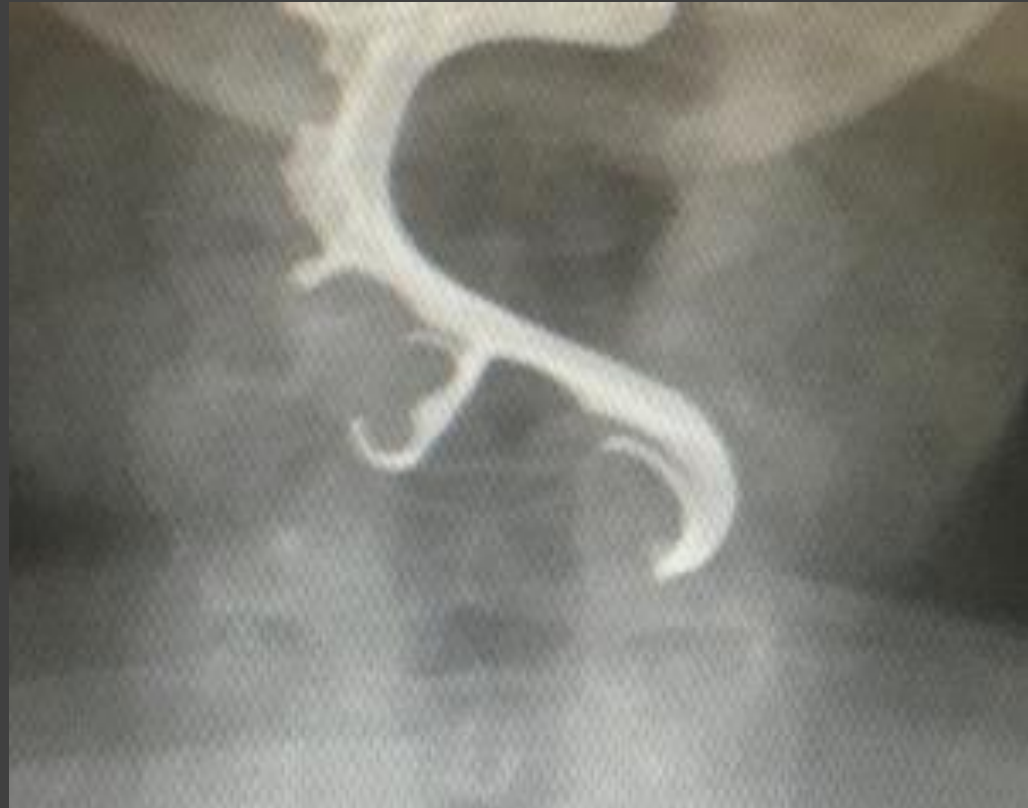Dental Prosthesis and other health conditions

Herpes Zoster

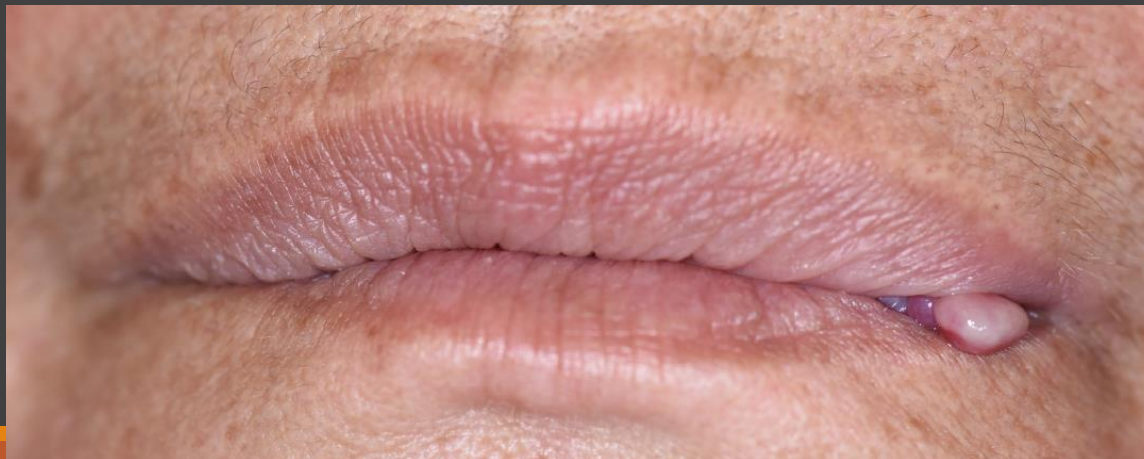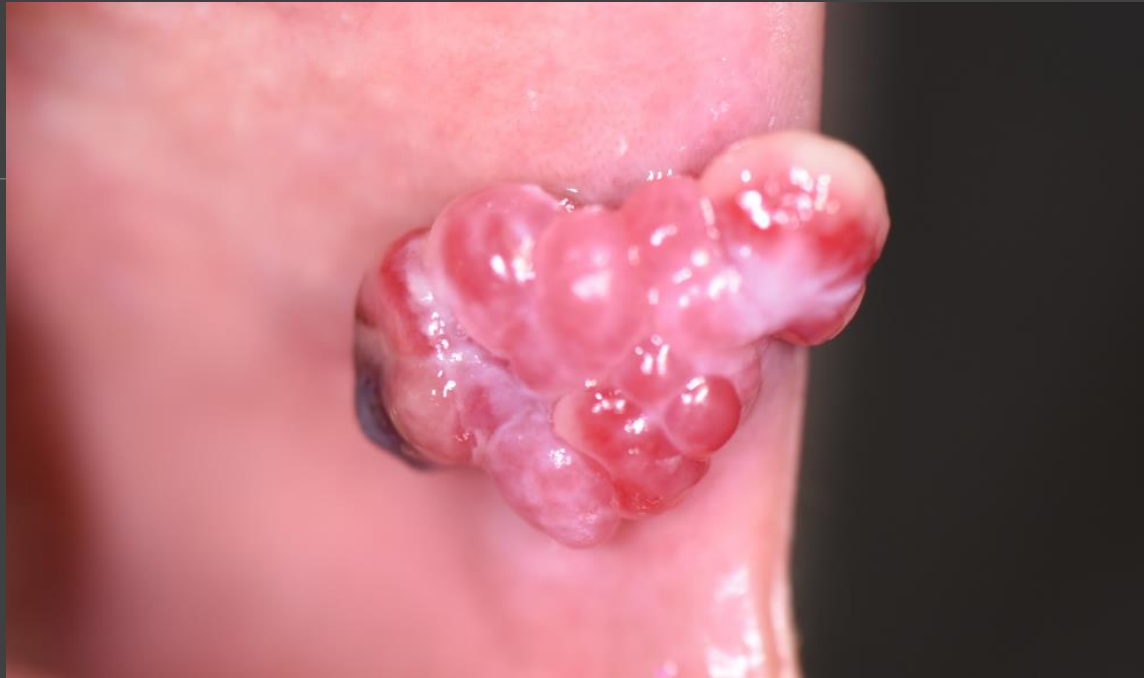- Varicella Zoster Virus (VZV) a human pathogen that effect 98% of the elderly in the U.S
- Bacterial superinfection of the lesions in oral cavity , usually due to Staphylococcus aureus
- Last longer in Older adults and painful



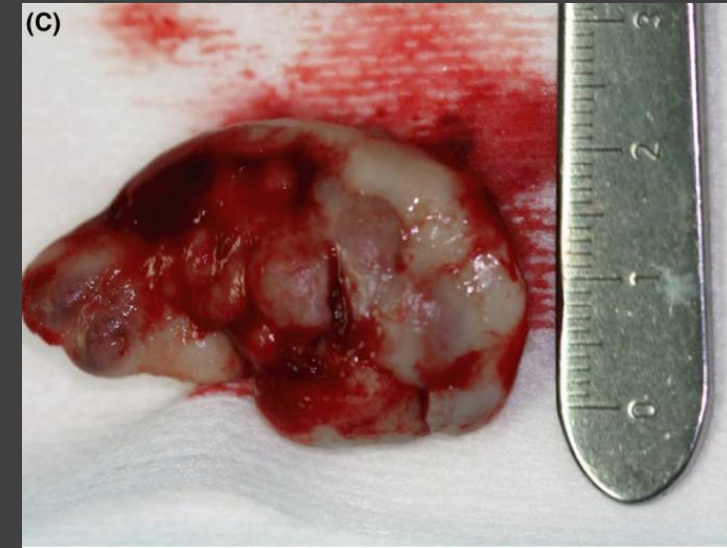
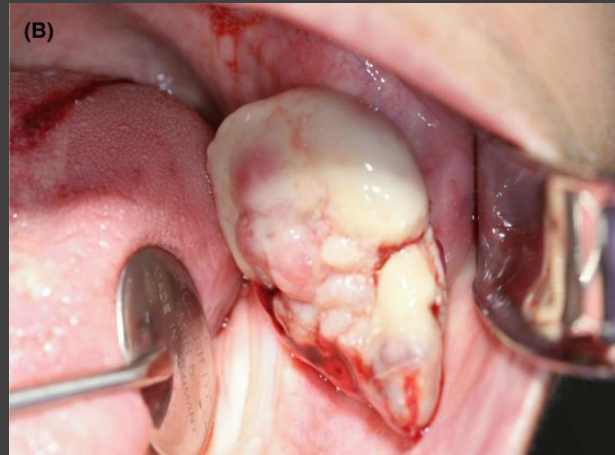
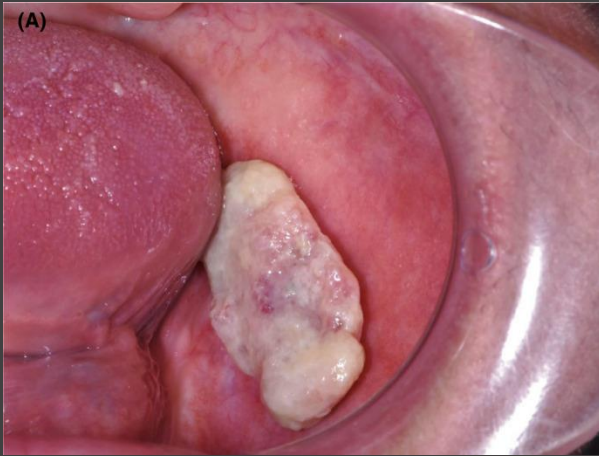
Swallowed an ill fitted Oral Prosthesis



...consider any
Abnormalities



Malignant Oral Lesions

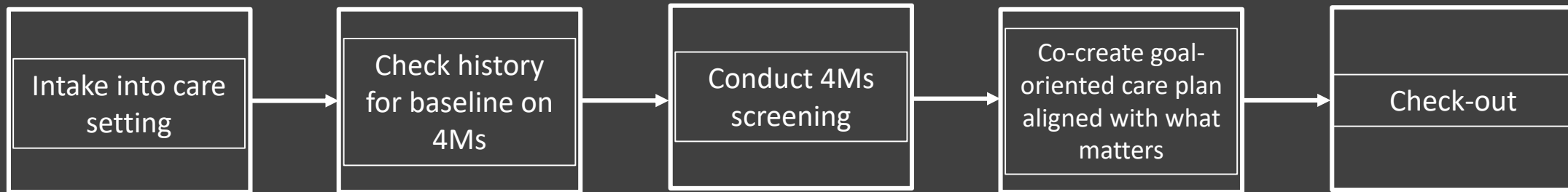
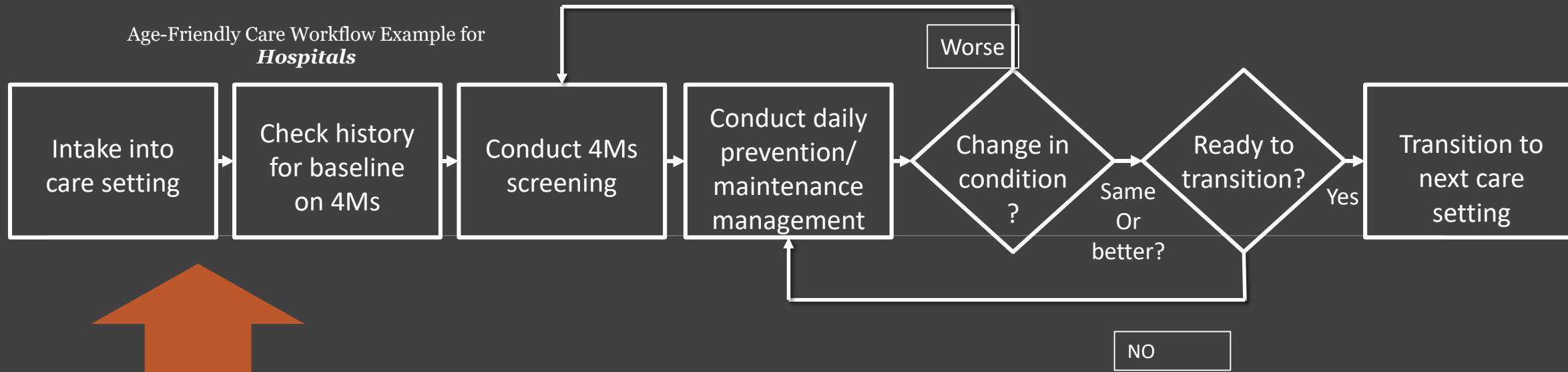


Patel, S., Barros, J., Nwizu, N. N., & Ogbureke, K. U. (2020). Metastatic renal cell carcinoma to the oral cavity as first sign of disease: A case report. *Clinical Case Reports*, 8(8), 1517-1521.

Healthy Aging Mouth...not always esthetically pleasing



Age-Friendly Care Workflow Example for *Hospitals*




Age-Friendly Care Workflow Example for *Primary Care*

Poll #2

Do you think oral health is the missing in Age Friendly Health System and Interprofessional education (IPE)?

Comments & Questions ?

maryam.tabrizi@uth.tmc.edu



<https://mojly.com/40-pics-of-people-with-funny-teeth-7524/funny-teeth-weird-pics-images-free-old-people-making-funny-smiling/>