

Grand Rounds

Solly Elmann, MD
SUNY Downstate Medical Center
Department of Ophthalmology
April 18, 2013



Case Presentation

An 84 year-old white male presents to the clinic for the first time, for routine examination, complaining only of mildly blurry vision in the right eye over the past few years, including worsened night vision.

Denies any other complaints, including pain, irritation, floaters, flashes, curtains, or any other symptoms.

History

PMH: Diabetes Mellitus II, HTN,
Hypercholesterolemia.

All well controlled.

POH: LP OS secondary to trauma over 40 years ago;
Ocular Hypertension OD “for many years;” s/p
CE/PCIOL OD

Gtts: Betoptic 2/2

All: nkda

SH/FH: negative

Examination

BCVA: 20/30 phni, LP

EOMS full ou

CVF: ftcf od

P: 6-4 mm od; +APD os

Tapp: 10/12

SLE:

LLA: Collarettes ou;
ectropion os

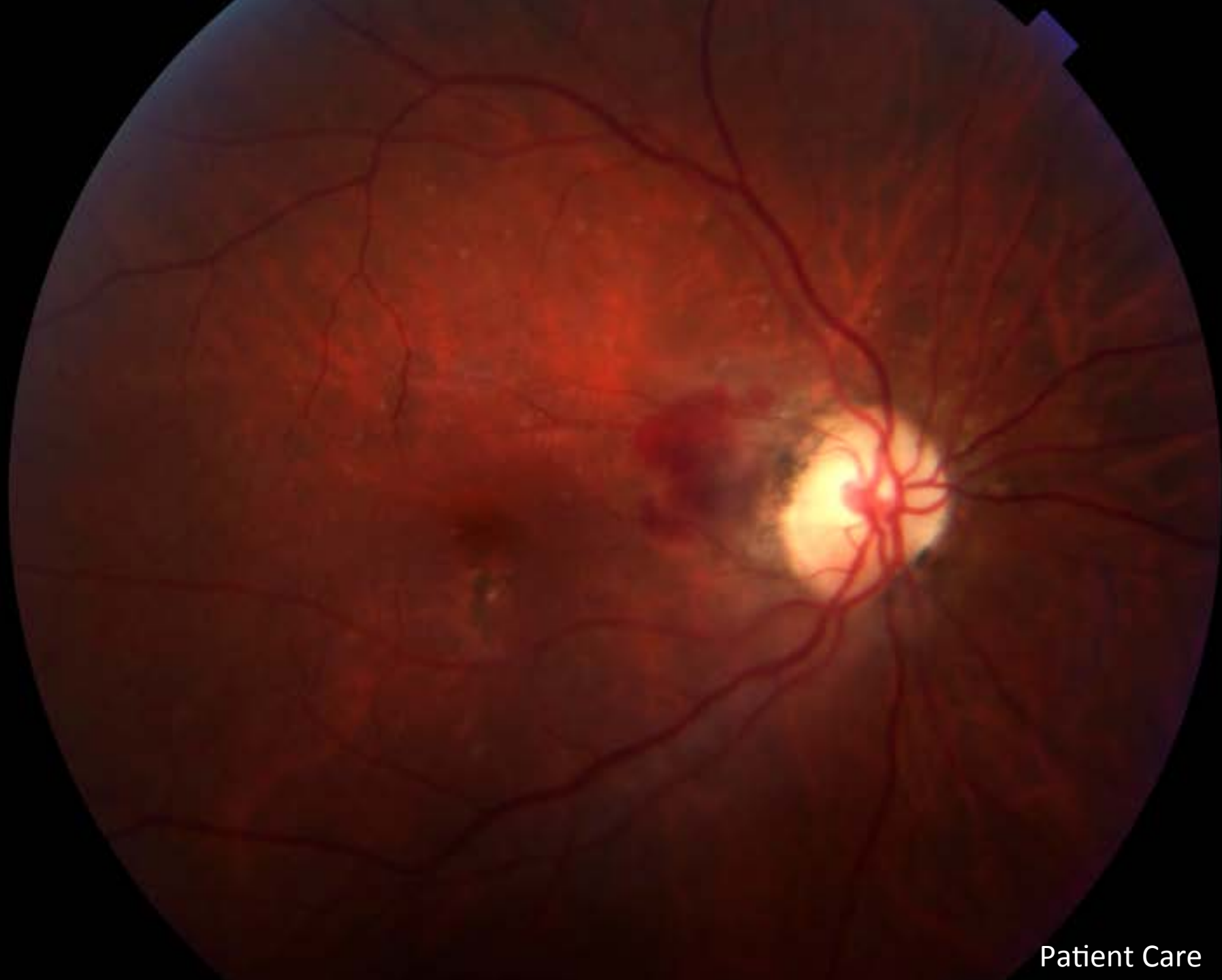
CS: w/q ou

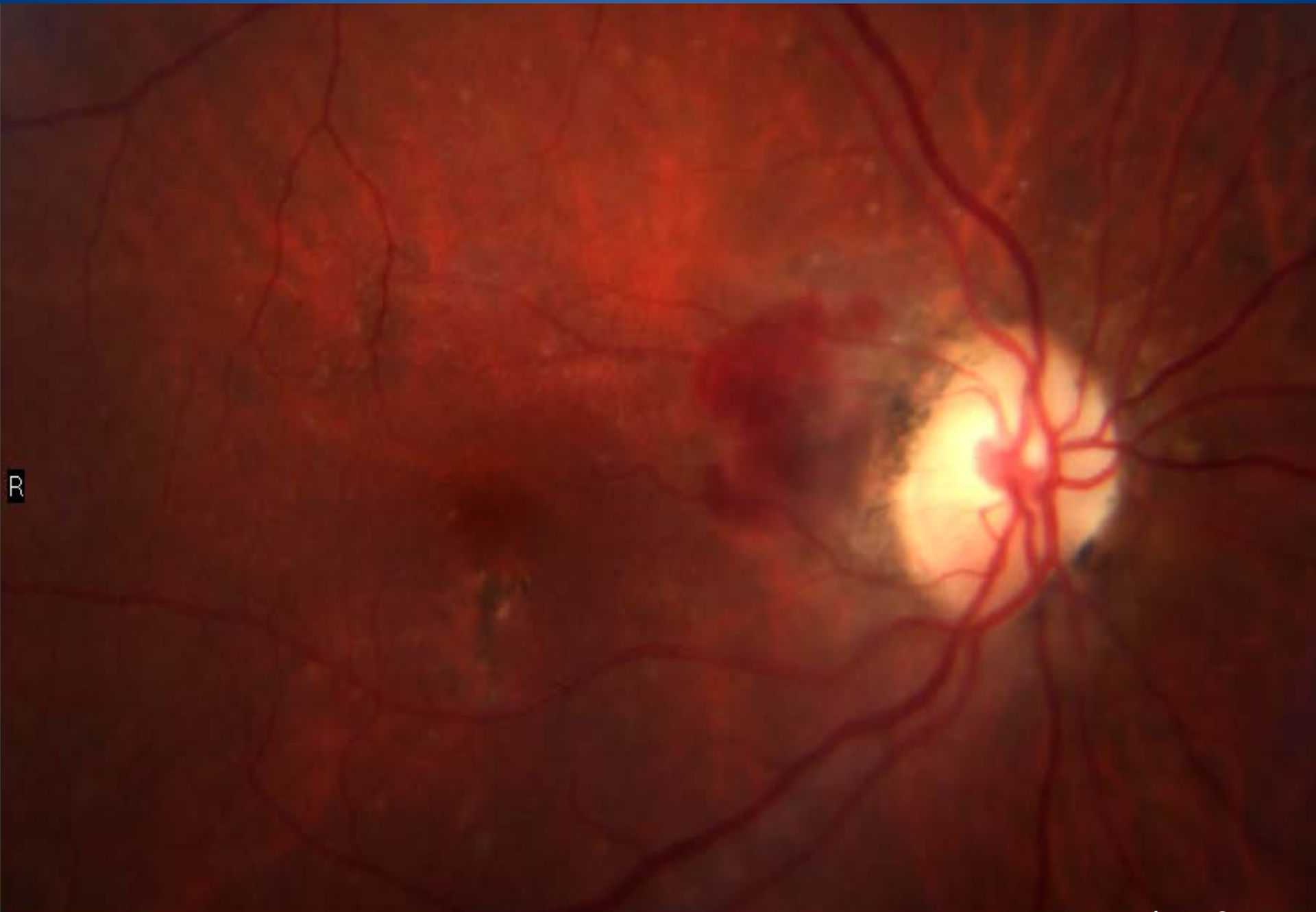
K: cl ou

AC: d/q ou

I/P: rr ou, no nvi

L: PCIOL, cl and
centered od; dense
white cataract os





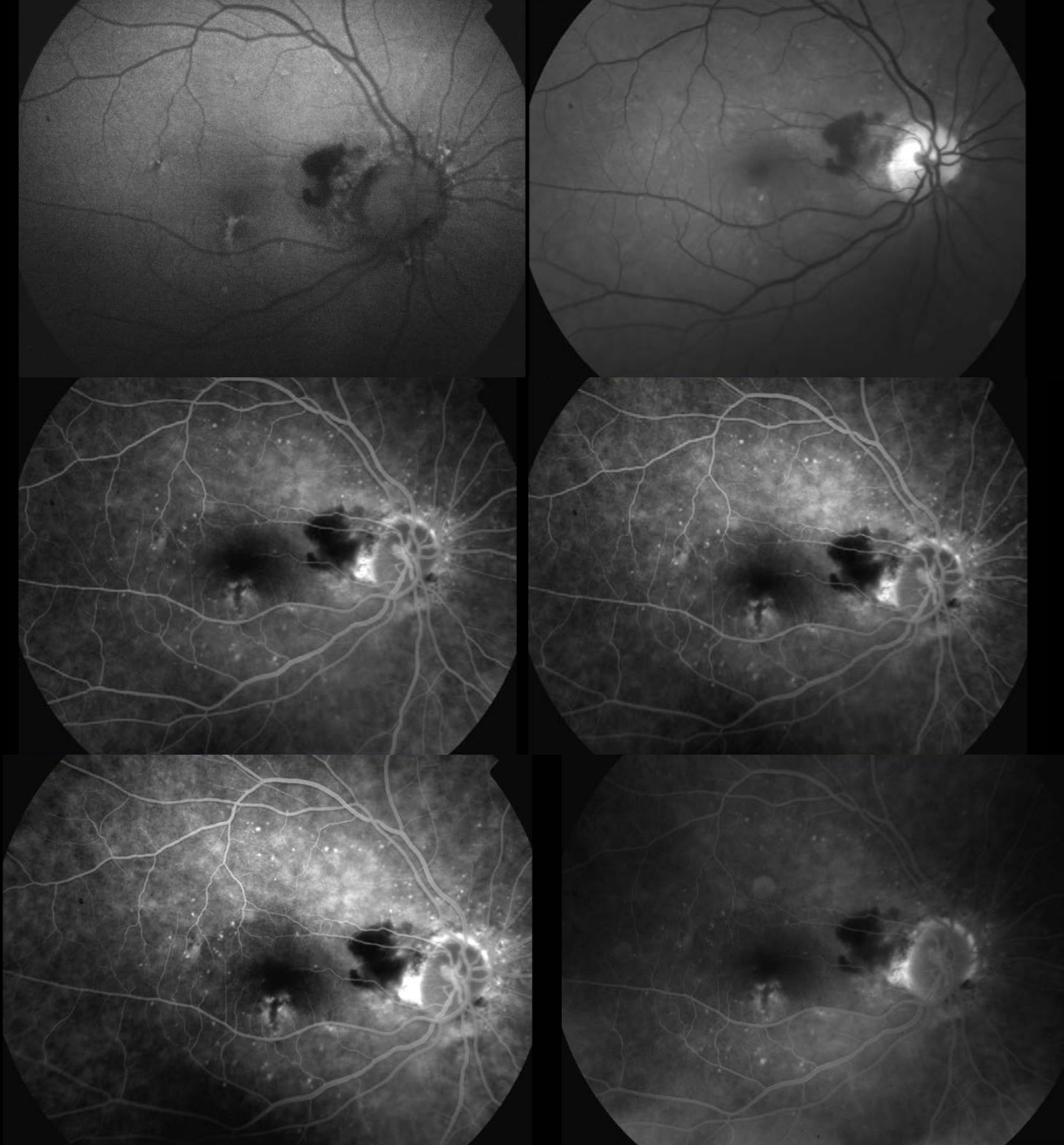
R

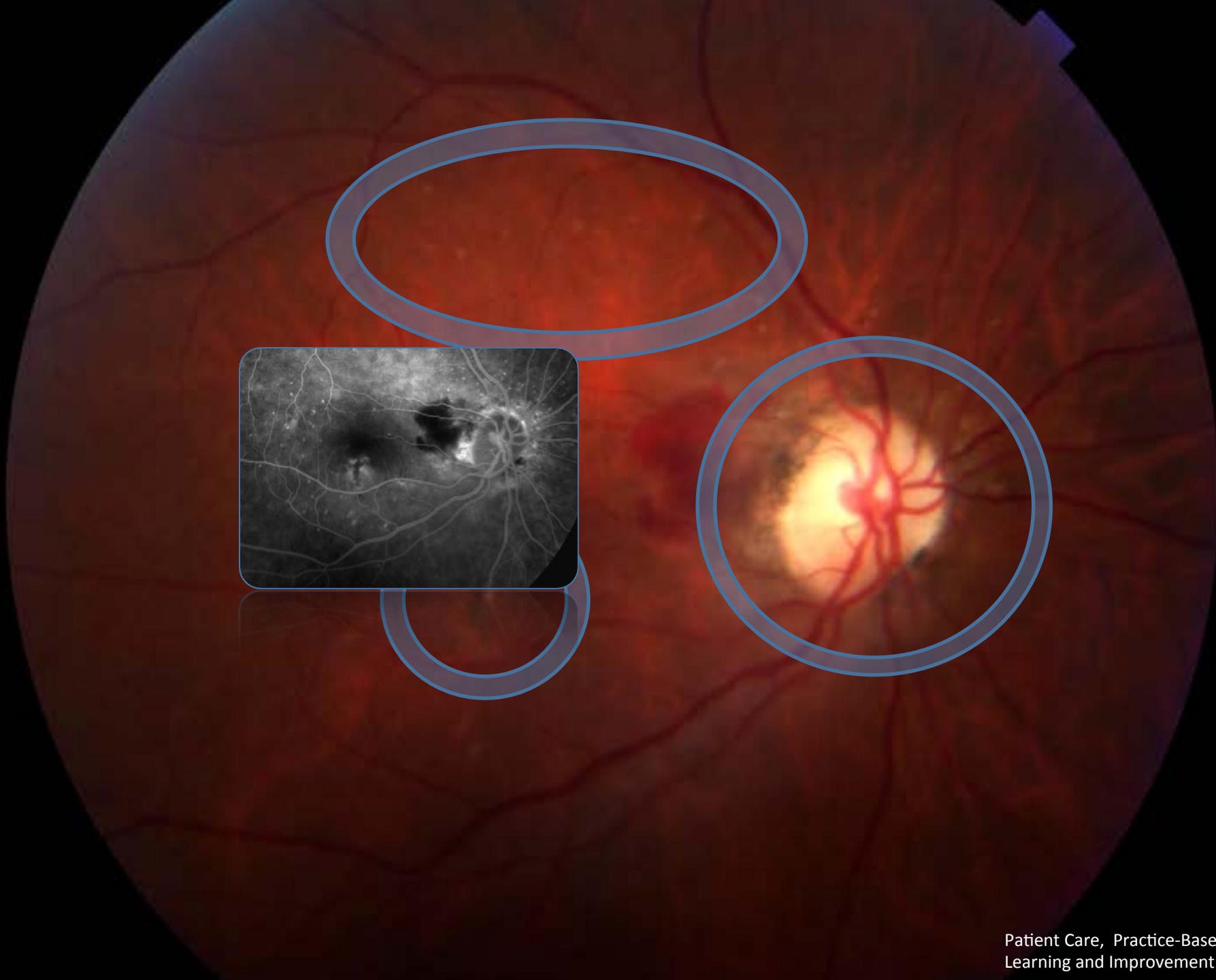
Differential?

Differential Diagnosis:

- Presumed Ocular Histoplasmosis Syndrome
- Multifocal choroiditis
- Prior choroidal rupture (prior history of trauma)
- Idiopathic Choroidal Neovascularization
- Age-Related Macular Degeneration
- Myopic degeneration (this patient is not myopic)
- Multiple Evanescent White Dot Syndrome

Next step?

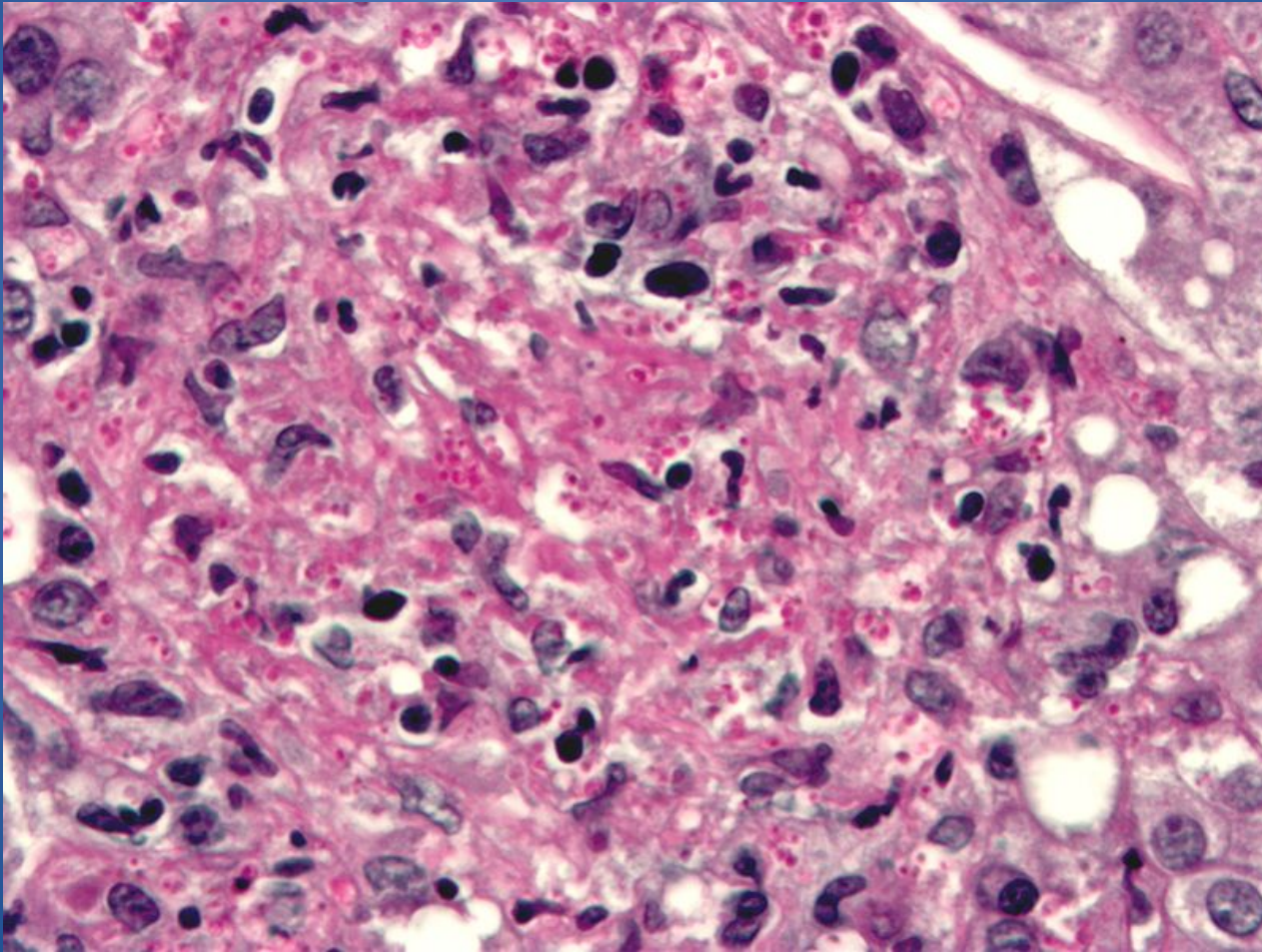





Presumed Ocular Histoplasmosis Syndrome

- A distinct clinical entity defined by specific signs:
 - Atrophic chorioretinal scarring
 - Peripapillary scarring
 - Maculopathy
 - Absence of vitritis
- “Presumed” secondary to exposure to *Histoplasma capsulatum*.
 - Rarely isolated or cultured from these eyes.

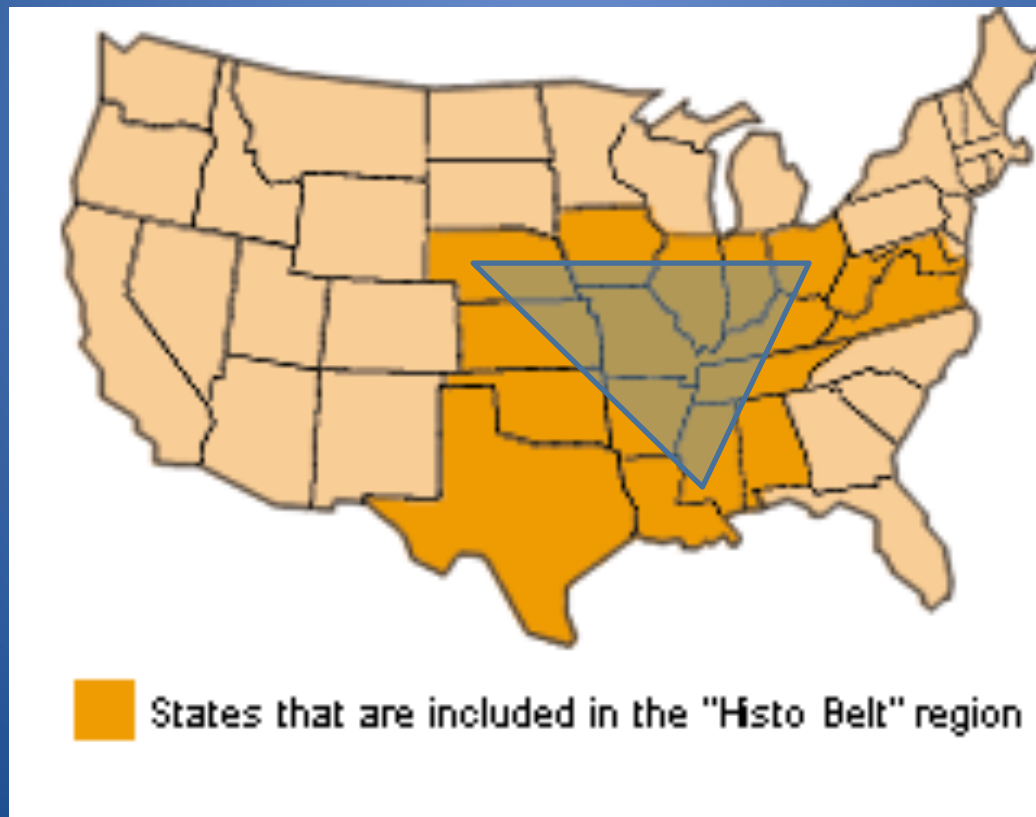
Histoplasma capsulatum

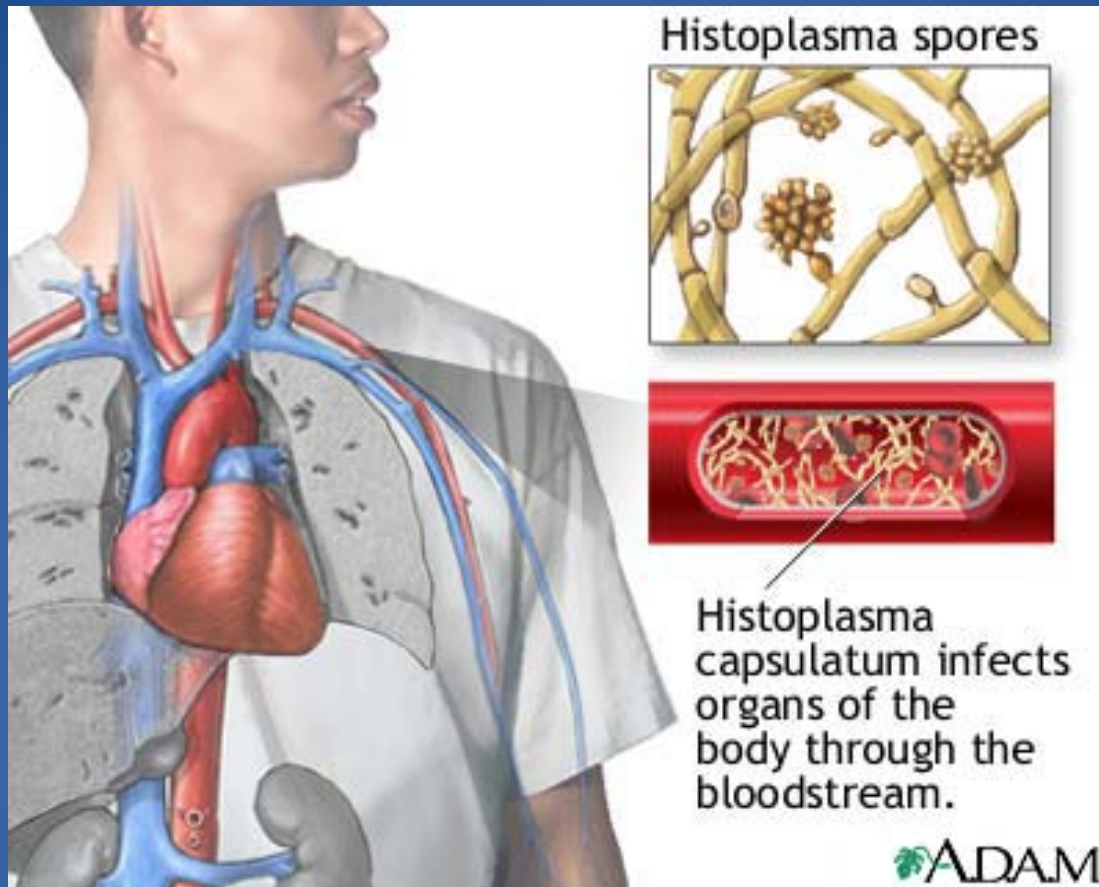




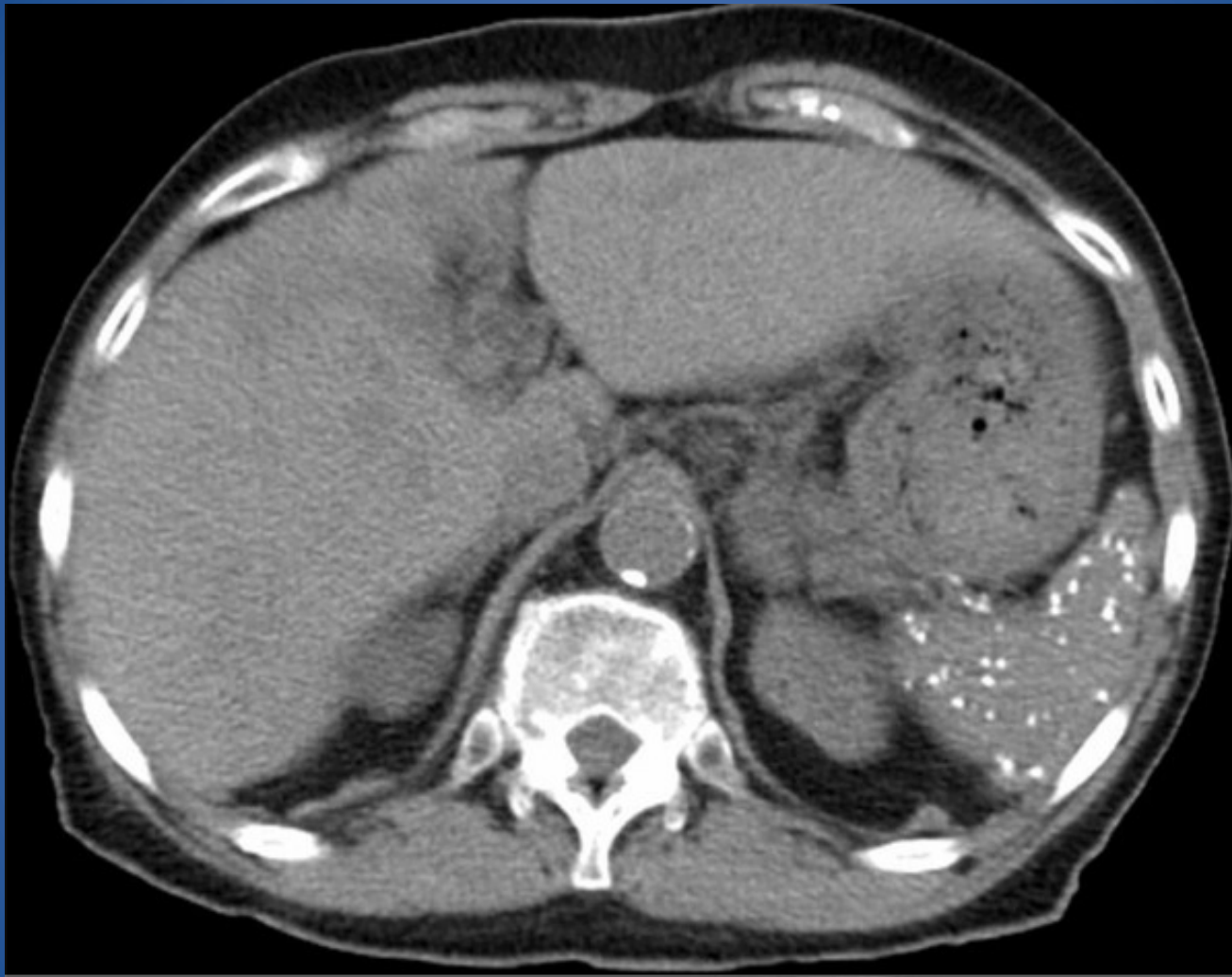The “Histo Belt”

- 60% of residents of the Ohio and Mississippi river valleys have positive histoplasmin skin testing
- Comstock: Triangle connecting Eastern Nebraska, Central Ohio, Southwestern Mississippi





Spores are inhaled, with an influenza-like prodrome. In few patients, a chronic cavitary pulmonary disease occurs. In immunocompromised patients, this may lead to disseminated granulomatous disease.



A Complicated History

1942: Reid: Atrophic chorioretinal lesions found in a patient with acute disseminated histoplasmosis

1959: Woods and Wahlen:

- “peculiar and consistent pattern of ocular lesions” in 19 patients
- Positive histoplasmin skin testing
- Atrophic pigmented or unpigmented peripheral lesions (“histo spots”), and late cystic lesions in the macula.
- Theory: prior disseminated histoplasmosis led to these chronic changes

1966: Schlaegel and Kenney:

- Optic nerve head lesions included in the spectrum of POHS

326

Alan C. Woods and Henry E. Wahlen

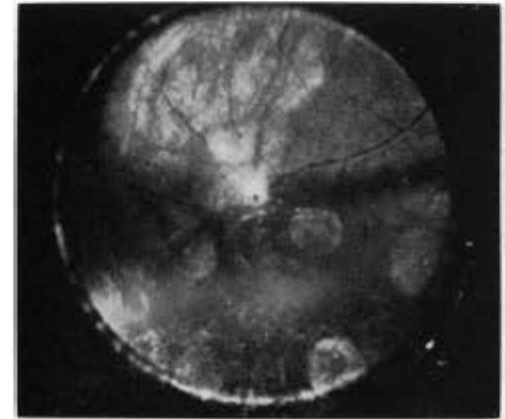


FIGURE 2. UNPIGMENTED, SMALL, PERIPHERAL LESIONS IN NASAL FUNDUS

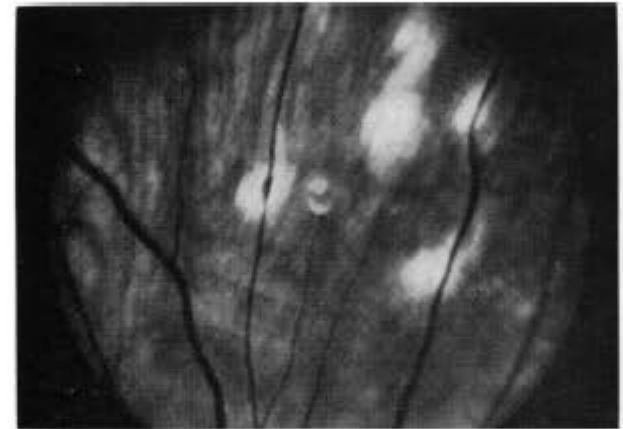


FIGURE 3. DISCRETE, SPARSELY PIGMENTED LESIONS IN PERIPHERAL FUNDUS

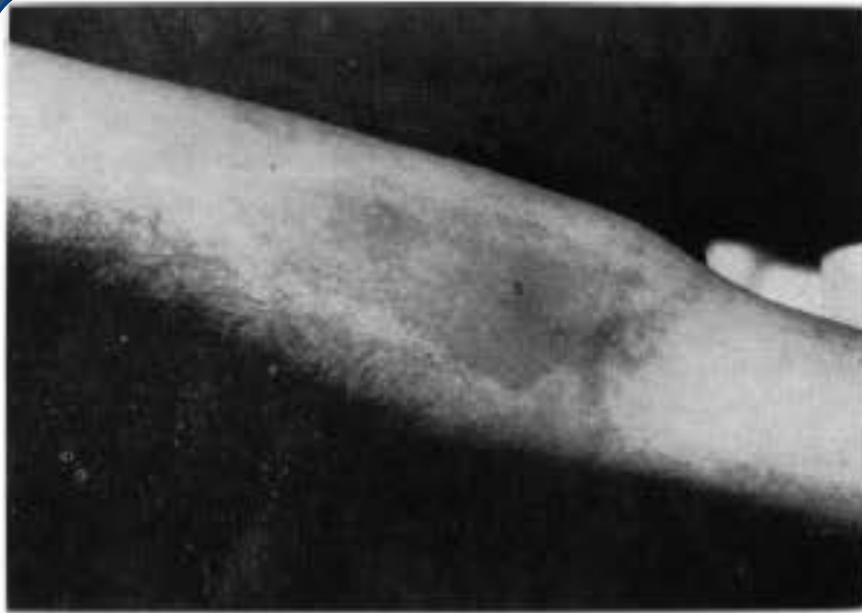


FIGURE 1. POSITIVE REACTION TO HISTOPLAMIN

FIGURE 1. POSITIVE REACTION TO HISTOPLAMIN

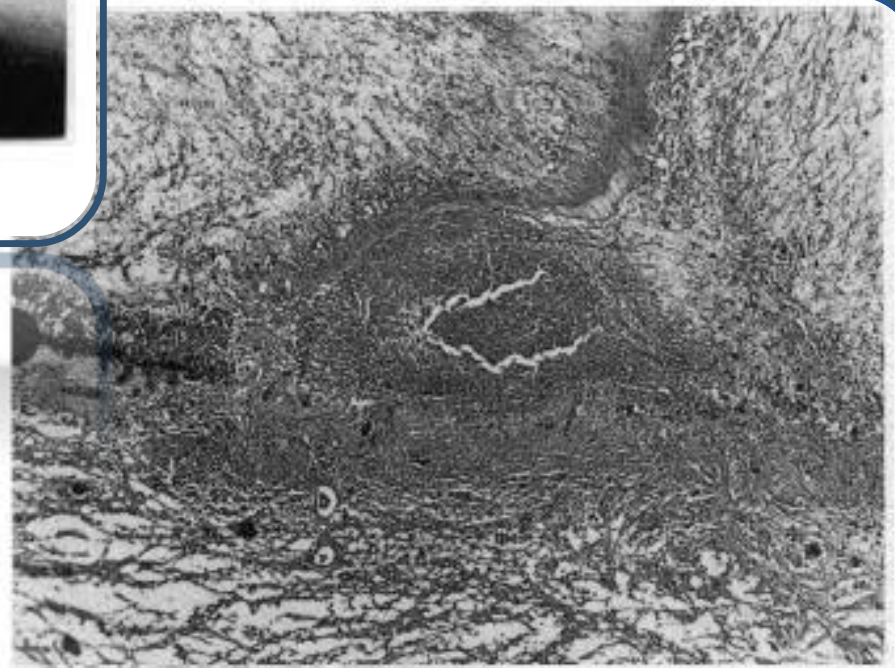


FIGURE 14. GRANULOMATOUS LESION OF PERIPHERAL FUNDUS
Etiology unknown.

ΕΠΙΘΕΛΥ ΠΑΡΚΟΛΑ

FIGURE 14. GRANULOMATOUS LESION OF PERIPHERAL FUNDUS

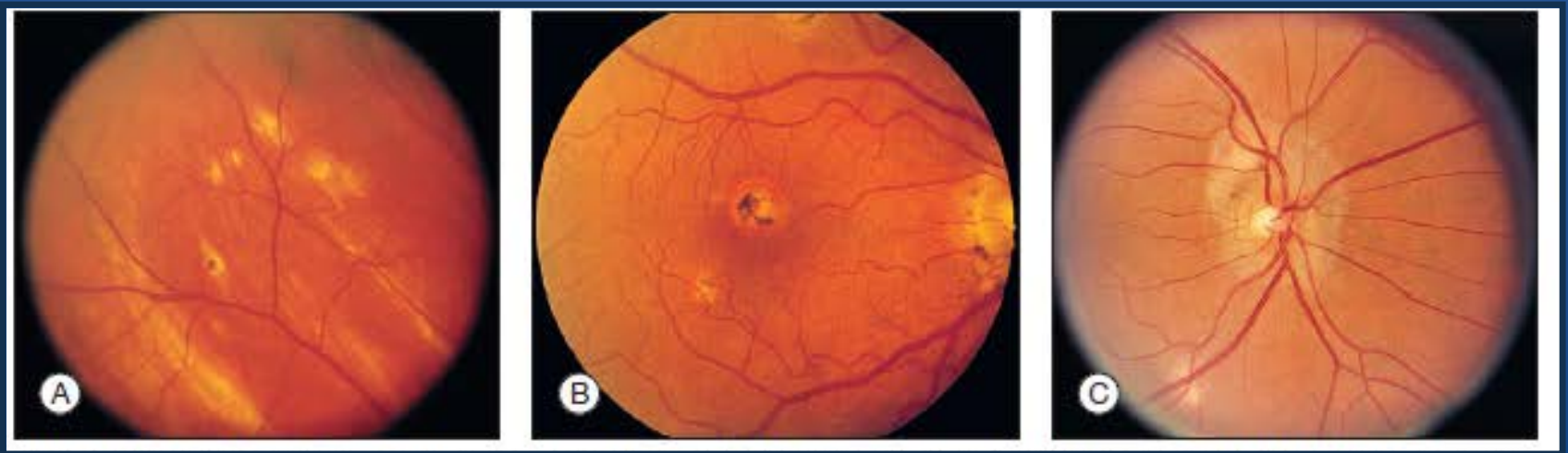Diagnosis

No ocular inflammation, plus two of the following:

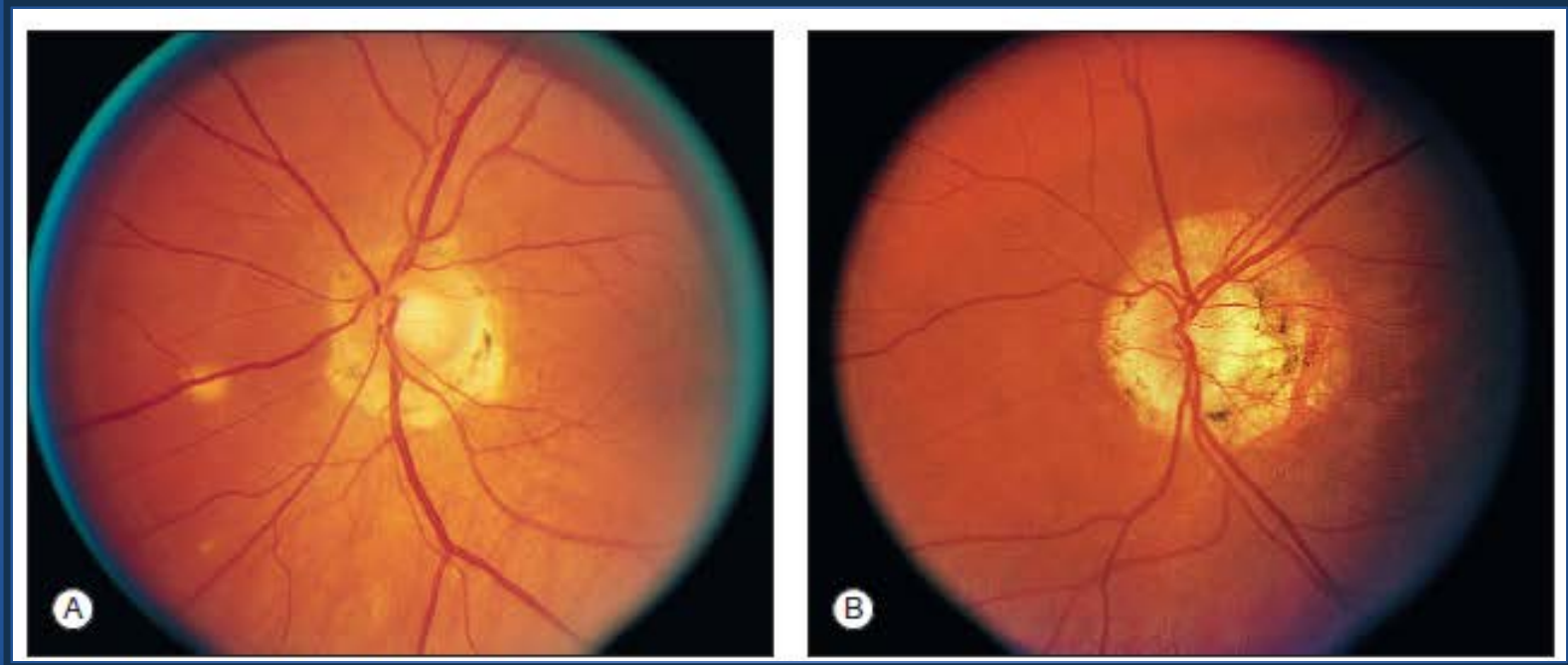
1. “Histo spots”
2. Peripapillary atrophy
3. CNV or CNV-related sequelae

Histo Spots

Discrete, focal, atrophic, punched-out choroidal scars in the macula or periphery, smaller in size than the optic disc.



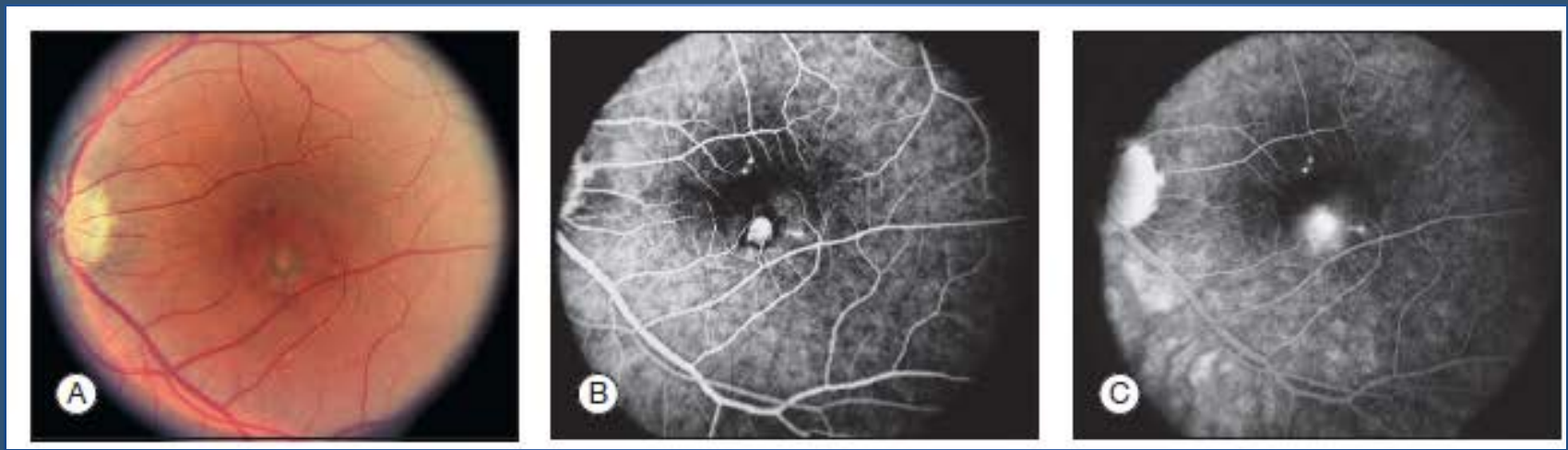
Peripapillary Atrophy

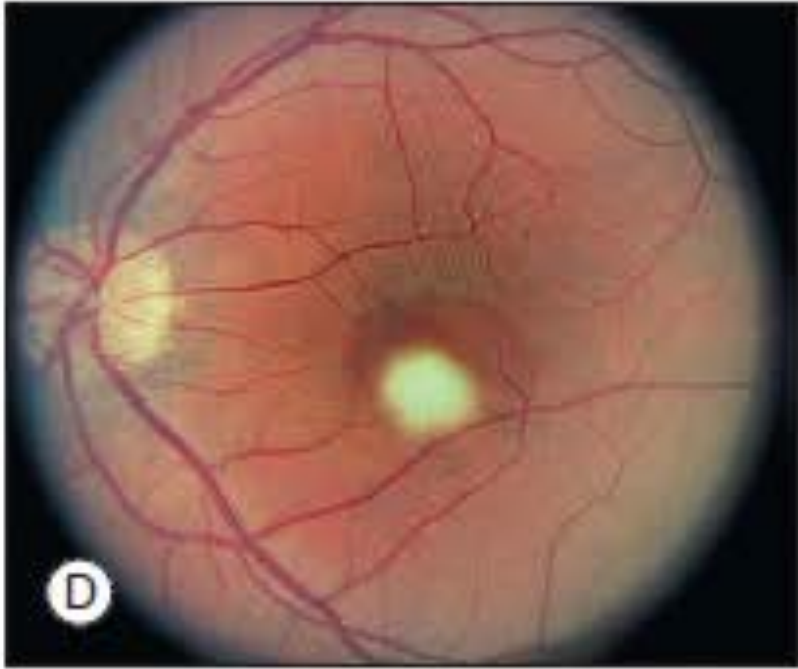


CNV or Associated Sequelae

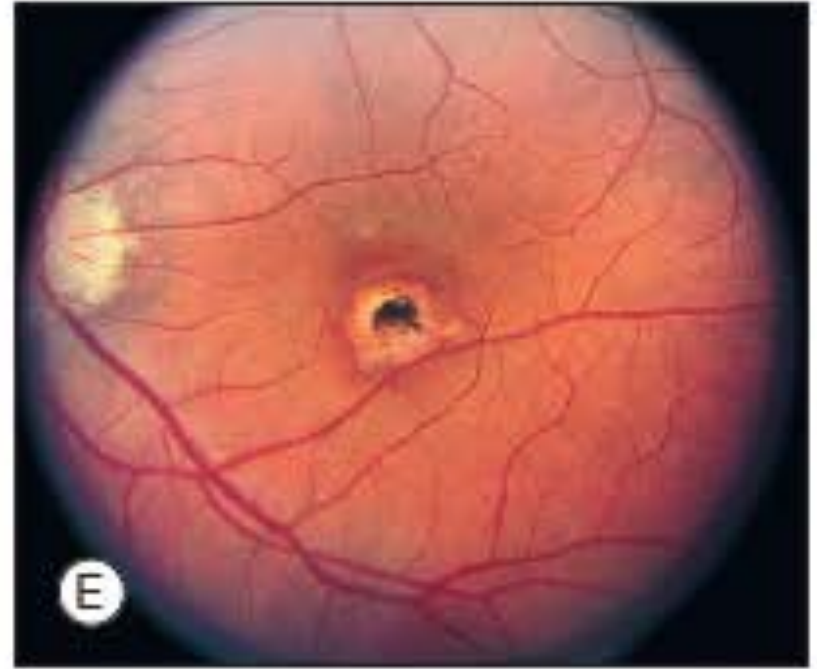
CNV

Associated sequelae: Hemorrhagic retinal detachment, fibrovascular disciform scar





One day post treatment



Two years post treatment

Other Pearls

- Usually bilateral
- Often asymmetric
- Seeing the initial granulomatous disease is rare

So... is this Histoplasmosis?

Although it is well-established that POHS and *Histoplasma capsulatum* are associated, **causality has not been completely established.**

1964

Specific Ocular Uveal Lesions in Patients with Evidence of Histoplasmosis and Toxoplasmosis

THOMAS E. VAN METRE, JR., M.D., DAVID L. KNOX, M.D., and
A. EDWARD MAUMENEE, M.D.,† *Baltimore, Md.*

Almost all patients with POHS in the USA have history of living in an endemic area.

Positive histoplasmin skin testing occurs more frequently in patients with ocular histoplasmosis compared with controls.

1967

PRESUMED HISTOPLASMIC CHOROIDITIS

T. F. Schlaegel, Jr.

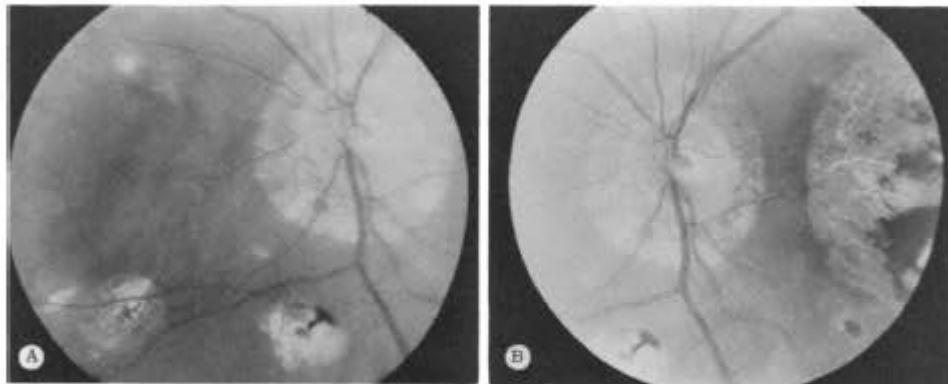
Following histoplasmin skin testing, histo lesions have been shown to activate

PRESUMED CHRONIC OCULAR HISTOPLASMOSIS SYNDROME: A CLINICAL-PATHOLOGIC CASE REPORT*

BY *A. Ray Irvine*, MD, *William H. Spencer*, MD,
Michael J. Hogan, MD,† *Roberta L. Meyers*, MD (BY
INVITATION), AND *S. Rodman Irvine*, MD

INTRODUCTION

ONE OF US (S.R.I.) HAS STUDIED A PATIENT SINCE 1957 FOR BILATERAL OCULAR findings consistent with the presumed ocular histoplasmosis syndrome. The left eye had to be enucleated because of a choroidal malignant melanoma. The histologic changes in the enucleated eye, studied by light and electron microscopy and by fluorescent antibody techniques, together with the clinical changes observed in both eyes, furnishes the basis for this report.



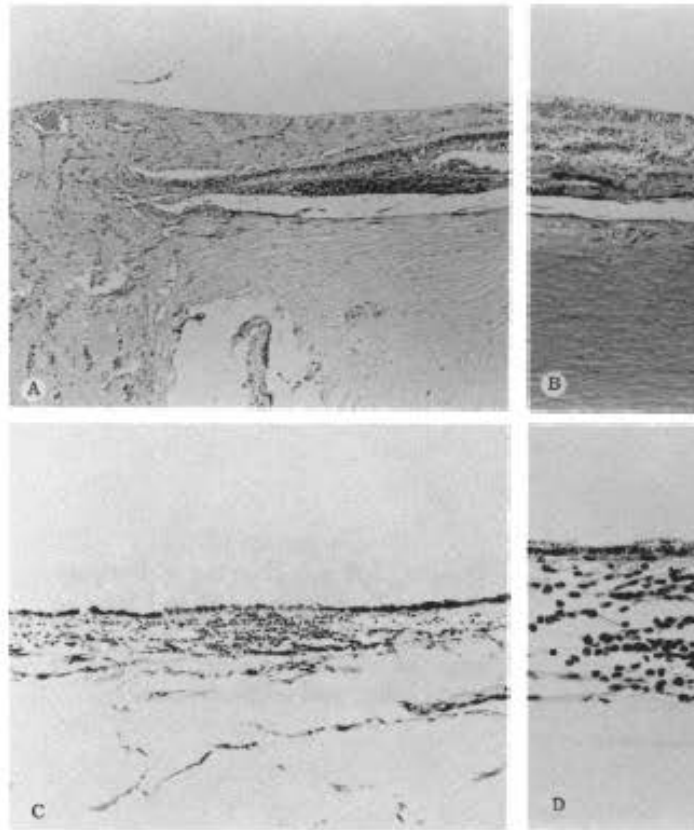


FIGURE 2

A: Peripapillary lesion. The choroid is infiltrated with round cells and of the outer retinal layers.
 B: Macular scar with choroidal inflammation. Vascularized scar and inflamed choroid. Early cystoid changes are present in the retina (magnification $\times 7$).
 C: Mid-peripheral lesion. Focal collections of lymphocytes and focal depigmentation of the retinal epithelium (hematoxylin and eosin, $\times 100$).
 D: Lesion (hematoxylin and eosin, $\times 100$).

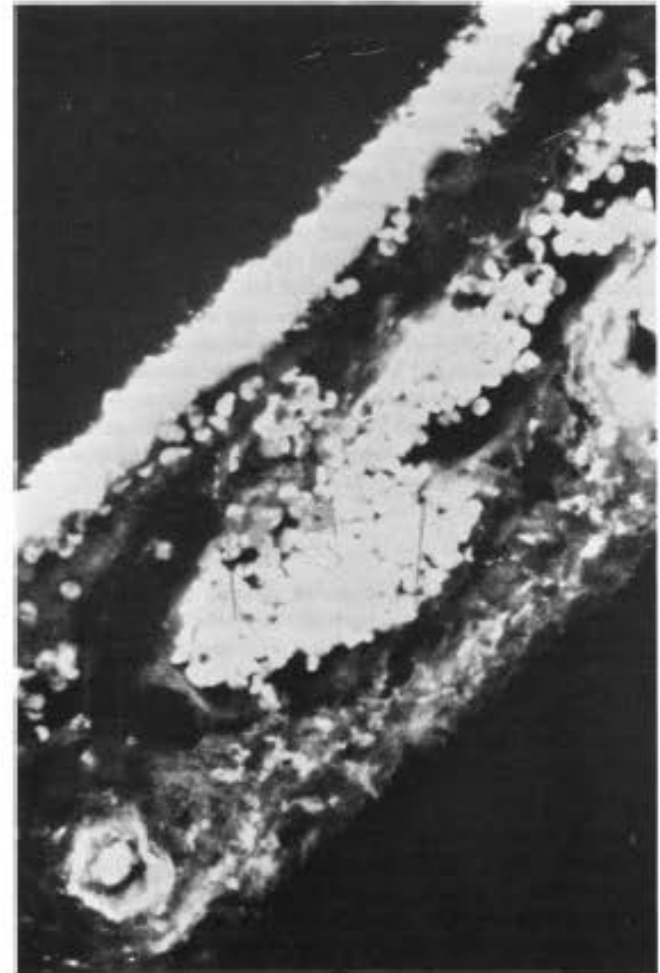


FIGURE 6

Chorioretinal lesion (magnification $\times 312$). Positive indirect fluorescence for histoplasma antigen. Ocular section reacted with patient serum then FITC-labeled sheep anti-human IgG. Similar staining noted with hyperimmune rabbit antihistoplasma serum on adjacent ocular section which was subsequently reacted with sheep anti-rabbit IgG.

DISCUSSION

Despite the history of intermittent clinical activity throughout the course of his disease, we were not prepared to find so much histologic evidence of chronic inflammation in the peripapillary, macular, and peripheral lesions. There was no clinical evidence of activity of any of the lesions at the time of enucleation and the fluorescein angiogram showed no evidence of subretinal neovascularization in any of the lesions including the one in the macula where the dense disciform scar presumably obscured these vessels.

implications of these findings. The presence of chronic inflammation and the immunohistopathologic findings suggest that an immune complex related to histoplasma capsulatum antigen is present. This may be considered as evidence of a continuing chronic inflammatory stimulus from retained antigenic fragments of the organism or from extraocular antigen. An alternative mechanism of recurrent inflammation would be to postulate an initial acute infection followed by degeneration, scarring, and neovascularization with intermittent vascular decompensation on a non-immune basis. "Histo spots" have been clinically described to wax and wane.³ This may be due to corresponding fluctuations in the choroidal lymphocytic infiltration. Although our patient had a varied clinical course, we did not observe any one of his lesions to regress.

Detection of *Histoplasma capsulatum* DNA in Lesions of Chronic Ocular Histoplasmosis Syndrome

William H. Spencer, MD; Chi-Chao Chan, MD; De Fen Shen, PhD; Narsing A. Rao, MD

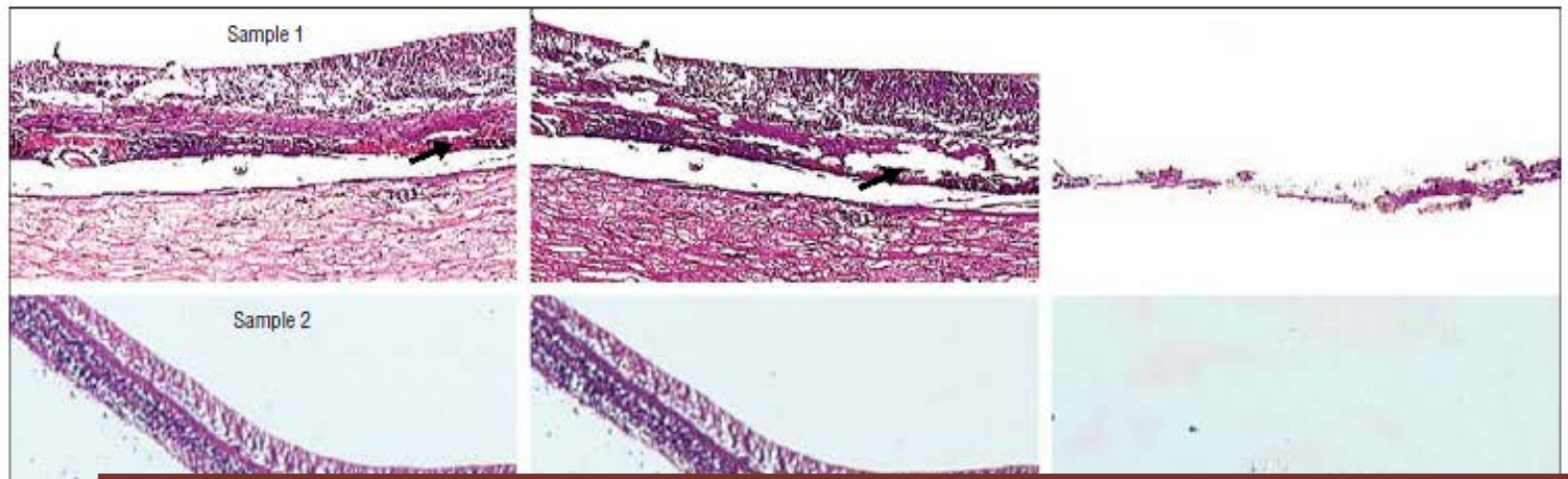


Figure 4.
for micro

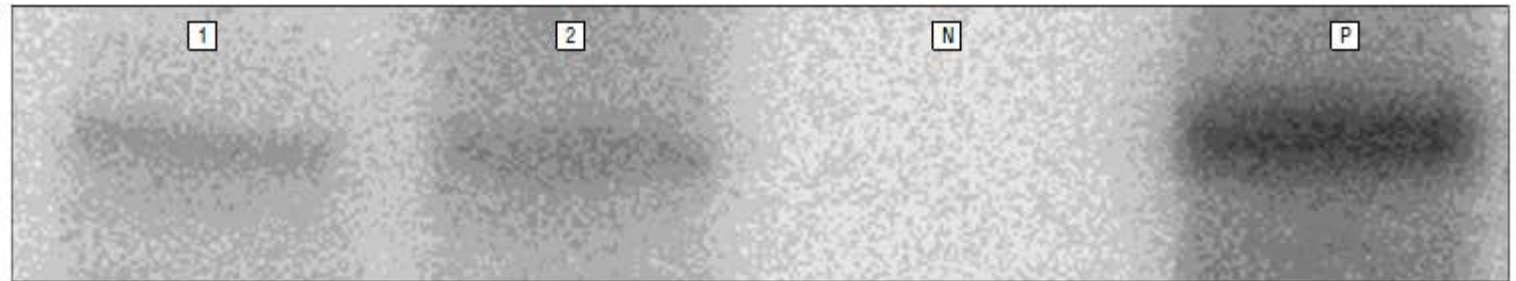


Figure 5. Gel electrophoresis of samples 1 and 2, negative control sample (N), and positive control sample (P). The dark lines in lanes 1, 2, and P demonstrate migration of each DNA product to the same level in the gel.

However...

- A clinical syndrome nearly identical to POHS is found in the UK and Europe, in patients that have never visited an endemic area, without positive histoplasmin skin testing.
- *H. Capsulatum* has never been identified in the UK.
- Amphotericin B has been shown not to be effective in treating POHS.

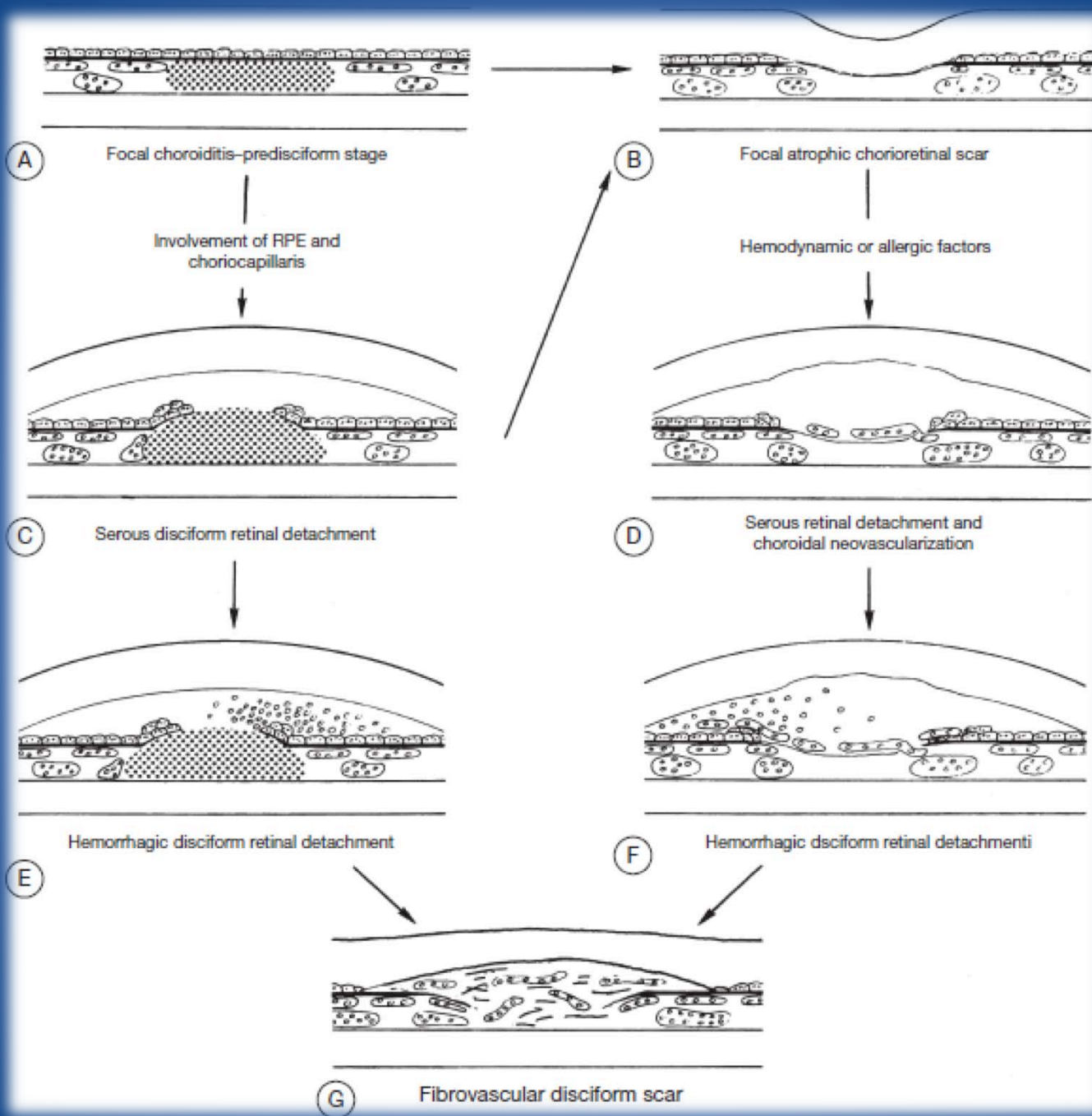
Genetic Susceptibility?

- HLA-B7 and HLA-DRw2 have been isolated in higher quantity in disciform lesions and histospots.
- There may be a component of genetic susceptibility either:
 - To histoplasmosis primary infection
 - To ocular histoplasmosis

Pathogenesis

(the most widely accepted theory)

1. Acute disseminated infection
2. Focal infection of the choroid
- 3a. Inflammatory and infectious process disrupts Bruch's Membrane and causes atrophic scarring
- 3b. Infection spreads to the RPE and choriocapillaris → subretinal hemorrhage/exudate with a fibrovascular scar
4. CNV



Choroidal Neovascularization

Multiple factors and theories:

- Disruption of Bruch's Membrane:
 - access to subretinal space
- HLA typing: genetic predisposition?
- Larger fungus inoculum
- Reinfection
- Hypersensitivity
- Higher proangiogenic factors, e.g. VEGF

Natural History

- Asymptomatic initially
 - Rarely, atrophic scars may cause some visual disturbances
- Often, presentation of patient is only when vision loss occurs secondary to hemorrhage and exudation, decades after initial infection and scarring
 - Middle aged individuals are most commonly affected
- Spontaneous recovery has been reported in the Macular Photocoagulation Study.

Impairment

- In Tennessee: POHS responsible for 2.8% of blindness in individuals applying for governmental support.
- In Maryland: No difference in visual impairment in individuals with and without histo spots.
- Submacular Surgery Trials Research Group: Bilateral CNV secondary to POHS had similar impairment to patients with AMD

Treatment

What doesn't work:

- Avoidance of valsalva
- Hyposensitization/Desensitization to Histoplasmin
- Immunosuppressants
- Photocoagulation (on inactive lesions)
- Amphotericin B

- Nothing has been shown to work on inactive lesions.
 - Most spontaneously involute.

Photocoagulation

- Macular Photocoagulation Study (MPS)
 - Two randomized control trials; argon laser vs observation; 262 patients
 - At least 200 μm from the FAZ
 - Enrollment was halted after it was clear that argon laser photocoagulation was superior to observation:
 - Extrafoveal CNV at 5 years: 44% in observed eyes vs. 9% in treated eyes
 - Juxtafoveal CNV at 5 years: 28% in observed eyes vs. 12% in treated eyes
 - Major complication: permanent scotoma secondary to laser photocoagulation
 - Not to be used on foveal lesions.

Photocoagulation

- Macular Photocoagulation Study (MPS)
 - A second study was tried again in 1981, this time allowing patients with visual acuity up to 20/400 with juxtafoveal lesions
 - This study was also halted after it was clear that photocoagulation offers significant benefit.
 - 6-or more line loss: 11% in treated, 30% in controls
 - No contraindication to treatment of lesions in papillomacular bundle.

Photodynamic Therapy

- Verteporfin for Ocular Histoplasmosis Trial:
 - 45% of patients had improved vision
 - 9% with severe vision loss at two years
 - Mean number of treatments: 2.9 in first year; 1 in second
- Now approved by the FDA for subfoveal CNV due to POHS.

Anti-VEGF

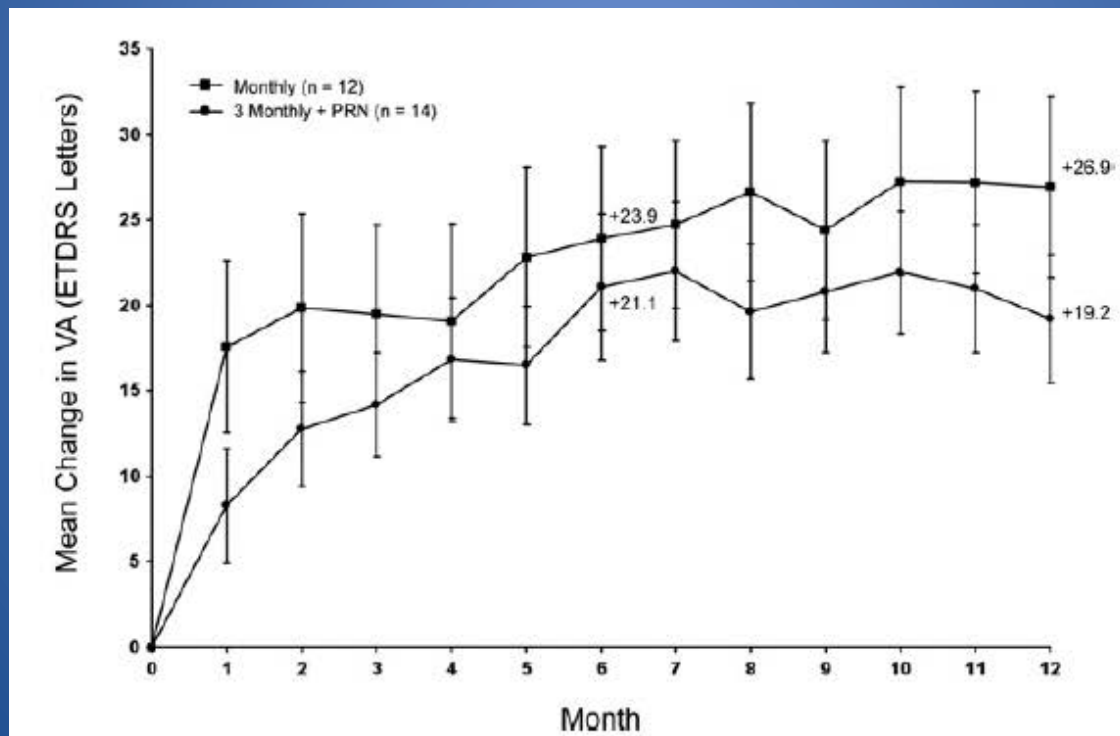
Ranibizumab for Choroidal Neovascularization Secondary to Causes Other Than Age-Related Macular Degeneration: A Phase I Clinical Trial

Jeffrey S. Heier, MD,¹ David Brown, MD,² Thomas Ciulla, MD,³ Prema Abraham, MD,⁴ Joy M. Bankert, RN,¹ Sandy Chong, BS,¹ Paul E. Daniel, Jr., BS,¹ Ivana K. Kim, MD⁵

- Phase-I randomized 12-month trial investigating ranibizumab for CNV for non-AMD patients; 30 patients
- 9 patients with POHS
- Monthly Ranibizumab vs 3-monthly injections followed by prn dosing at monthly visits
- 7.4 lines of improvement seen in monthly, 5.0 lines in prn group
- No significant differences between the groups at any time point
- No complications seen

Ranibizumab for Choroidal Neovascularization Secondary to Causes Other Than Age-Related Macular Degeneration: A Phase I Clinical Trial

Jeffrey S. Heier, MD,¹ David Brown, MD,² Thomas Ciulla, MD,³ Prema Abraham, MD,⁴
Joy M. Bankert, RN,¹ Sandy Chong, BS,¹ Paul E. Daniel, Jr., BS,¹ Ivana K. Kim, MD⁵



Other options

- Combination treatment:
 - PDT plus Anti-VEGF
- Triamcinolone:
 - not as effective, high complication rate, high failure rate

Submacular Surgery

- Prior to PDT and anti-VEGF therapy
- Recurrence rate of CNV higher for submacular surgery than for photocoagulation
- Submacular Surgery Trials Group:
 - 225 patients with non-AMD CNV, 192 with POHS
 - Vision improved or stable in 20% more patients with surgery
 - Not statistically significant: all of benefit in patients with 20/100 or worse baseline VA.
 - Quality of life scores improved with surgery

Macular Translocation

- Limited evidence in the literature
- Three cases of POHS treated with 360 degree MTL.
- 2/3 with improved VA, 2/3 with recurrent CNV, 2/3 with chronic CME

Mainstays of treatment

- Extrafoveal CNV: laser photocoagulation
- Subfoveal and Juxtafoveal CNV: anti-VEGF, PDT
- Select situations: surgery
- Inactive POHS: Observation

Our Patient

- Has received his first Avastin injection with improvement in vision after one month of one line (20/40- to 20/30)
- Has been offered a second injection one month after the first.
- Is very happy with improvement in vision.

Reflective Practice

This case taught me the value of a good differential diagnosis for choroidal lesions and CNV, and understanding of the criteria of diagnosis involved with POHS. I also learned the value of history taking and focusing on risk factors involved in a diagnosis. I worked together with the attending, senior residents ocular photographer, and the patient to agree on proper management and intervention modalities. The patient and I created good rapport and were able to agree on a plan together.

References

- Stephen J. Ryan et al., *Retina*, 3rd ed. (C.V. Mosby, 2001)
- Reid JD, Scherer JH, Herbut PA, et al. Systemic histoplasmosis diagnosed before death and produced experimentally in guinea pigs. *J Lab Clin Med* 1942;27:419–34.
- Schlaegel TF. Granulomatous uveitis: an etiologic survey of 100 cases. *Trans Am Acad Ophthalmol Otolaryngol* 1958;62:813–25.
- Woods AC, Wahlen HE. The probable role of benign histoplasmosis in the etiology of granulomatous uveitis. *Trans Am Ophthalmol Soc* 1959;57:318–43.
- Schlaegel TF, Kenney D. Changes around the optic nerve head in presumed ocular histoplasmosis. *Am J Ophthalmol* 1966;62:454–8.
- Schlaegel TF. *Ocular histoplasmosis*. New York: Grune & Stratton; 1977.
- Spencer WH, Chan C-C, Shen DF, et al. Detection of *Histoplasma capsulatum* DNA in lesions of chronic ocular histoplasmosis syndrome. *Arch Ophthalmol* 2003;121:1551–5.
- Braunstein RA, Rosen DA, Bird AC. Ocular histoplasmosis syndrome in the United Kingdom. *Br J Ophthalmol* 1974;58:893–8.
- Submacular Surgery Trials Research Group. Health- and vision-related quality of life among patients with ocular histoplasmosis or idiopathic choroidal neovascularization at time of enrollment in a randomized trial of submacular surgery. SST report no. 5. *Arch Ophthalmol* 2005;123:78–88.
- Macular Photocoagulation Study Group. Argon laser photocoagulation for neovascular maculopathy: five-year results from randomized clinical trials. *Arch Ophthalmol* 1991;109:1109–14.
- Macular Photocoagulation Study Group. Laser photocoagulation for neovascular lesions nasal to the fovea: results from clinical trials for lesions secondary to ocular histoplasmosis and idiopathic causes. *Arch Ophthalmol* 1995;113:56–61
- Comstock GW, Vicens CN, Goodman NL, et al. Differences in the distribution of sensitivity to histoplasmin and isolations of *Histoplasma capsulatum*. *Am J Epidemiol* 1968;88:195–209.
- Heier JS, Brown D, Ciulla T, et al. Ranibizumab for choroidal neovascularization secondary to causes other than age-related macular degeneration: a phase I clinical trial. *Ophthalmology* 2011;118:111–8.

Thank You

- Dr Shrier
- Dr Rubaltelli
- Christopher Minning
- Michael Dattilo
- Our Patient
and neighbor