



Ophthalmology Grand Rounds Case Presentation

Renelle Pointdujour, MD PL-1

September 15, 2011

Case Presentation- History

46 yo B M with no pmhx and no pohx c/o “foggy vision & distorted contours” of the right eye x 1 day. The patient states that objects have a wavy appearance in his superior visual field.

Pertinent Negatives:

ϕ flashing lights, ϕ floaters, ϕ complete vision loss, ϕ trauma, ϕ hx of refractive error

ϕ Pmhx; ϕ Meds; NKDA; ϕ Fmhx

Physical Examination

Vitals: bp 235/147

NVacc (Add+2.00) 20/20 ou

P: 4 to 2 mm ou, no apd

EOM: full ou

Tpen: 18 od; 18 os

CVF: full ou

Color Plates:

14/14 od; 14/14 os

Amsler grid:

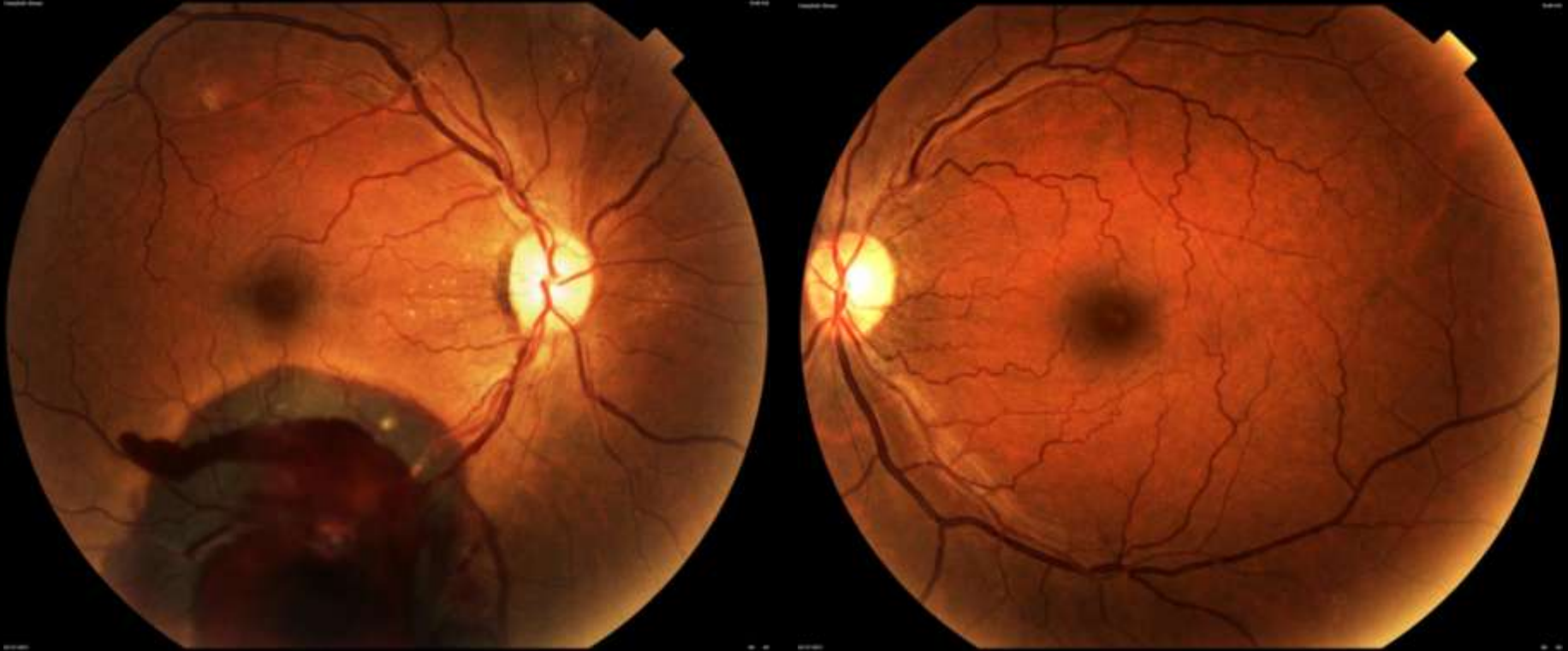+ abnormal superiorly od;

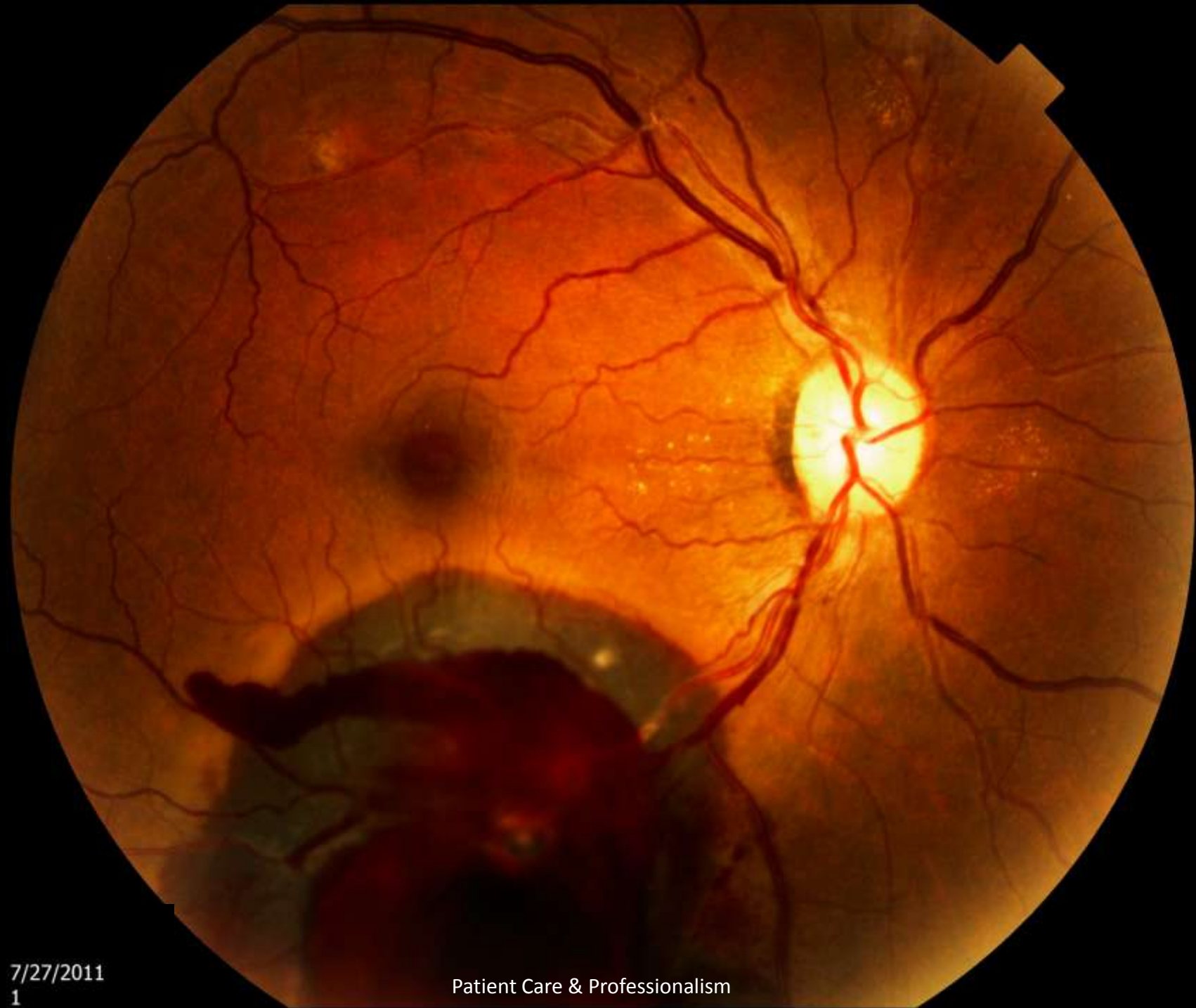wnl os

PLE

- LLA: wnl ou
- C/S: w & q ou
- K: clear ou
- A/C: formed ou
- IP: rrf ou
- L: +ns ou

DFE





7/27/2011

1

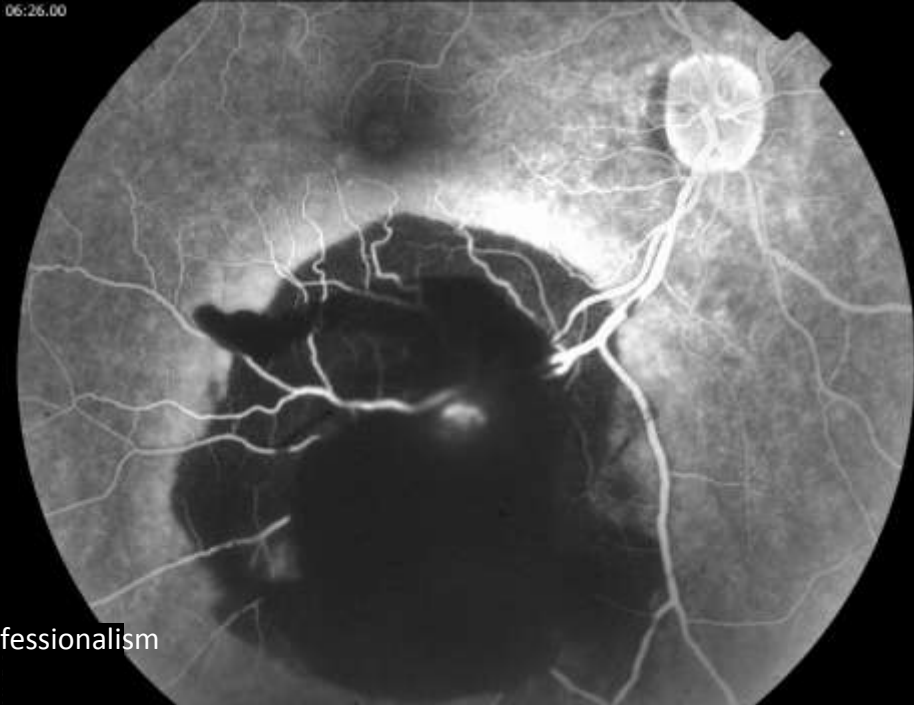
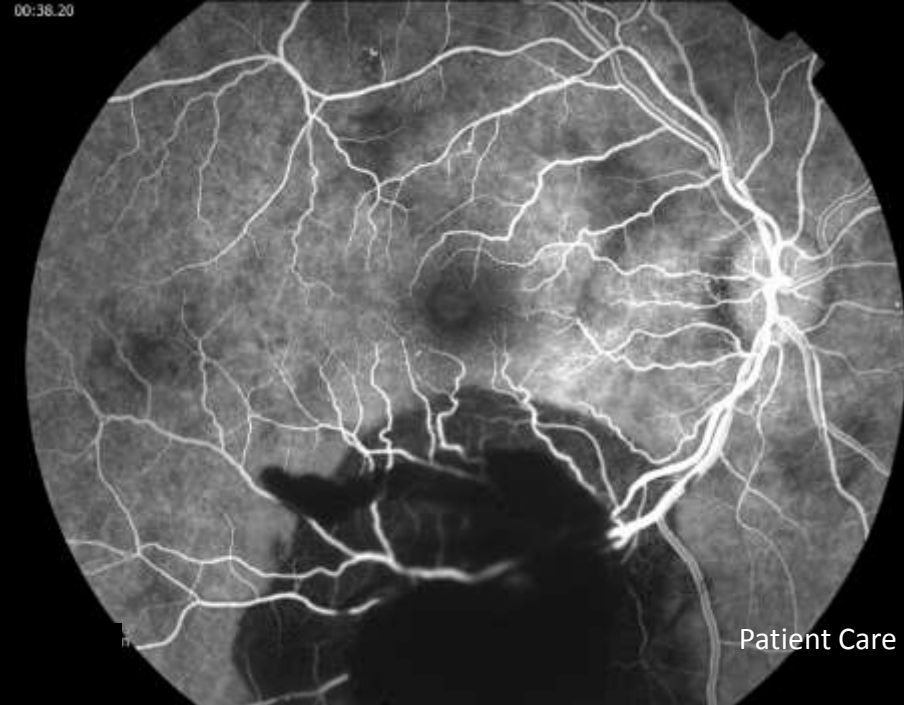
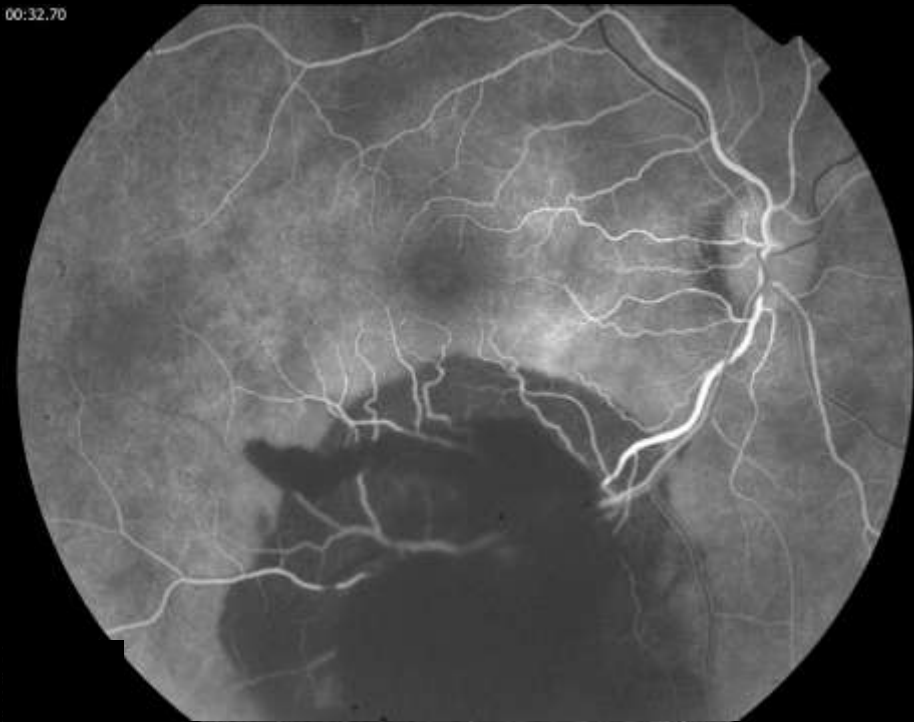
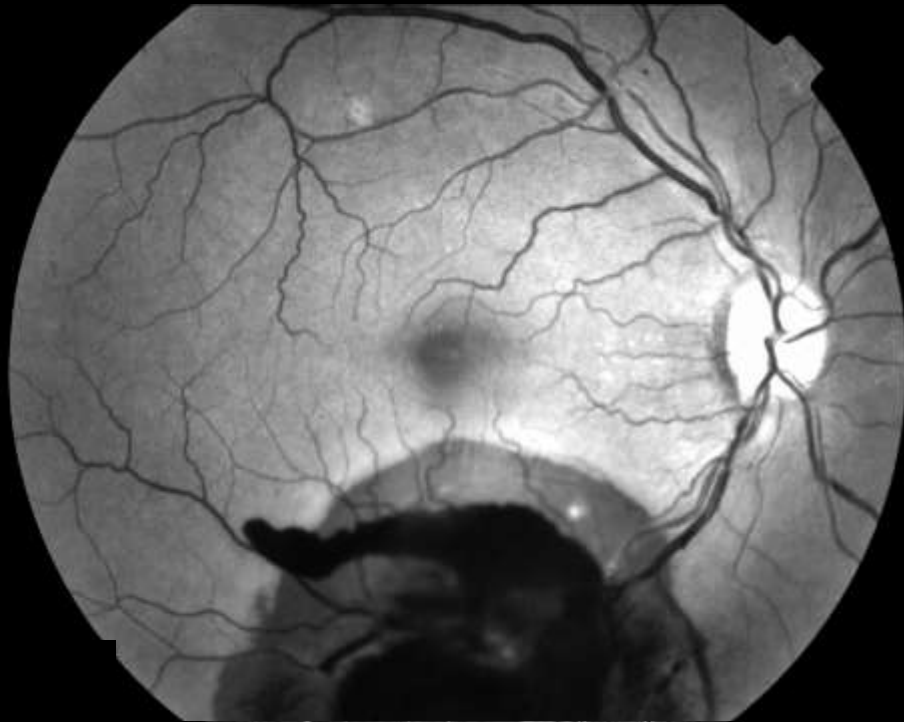Patient Care & Professionalism

DFE

- V- clear ou
- D- c/d 0.3 s/p ou
- M- macular edema od; flat os
- BV: + arterial dilation inferior to the macula od, +venous tortuosity ou, +AV nicking ou
- P: ~ 5-6 dd area of subretinal heme and retinal elevation inferior to the macula (~1 dd inferior to the fovea) with overlying preretinal heme; wnl os, no heme or detachment os

Imaging Modalities

- FA
- OCT
- Indocyanine Green Angiography
 - ICG may be a useful adjunct in cases with dense hemorrhage
 - Near-infrared range of absorption and emission allows the dye to penetrate through dense heme
 - ICG may leak less than fluorescein, thus providing well-defined images



Differential Diagnosis

- Retinal Arterial Macroaneurysm
- Capillary Hemangioma
 - Von Hippel Lindau
- Neovascular AMD
- Choroidal Neovascularization
 - extramacular
- Idiopathic polypoidal choroidal vasculopathy
- Juxtafoveal telangiectasis
- Valsalva retinopathy
- Diabetic Retinopathy
- Radiation Retinopathy
- Coats Disease
- Retinal Vein Occlusion
- Choroidal malignant melanomas
- IRVAN (Idiopathic vasculitis, aneurysms, and neuroretinitis syndrome)
- Terson Syndrome
- Trauma

Retinal Arterial Macroaneurysm

- DEFINITION
 - Localized fusiform or saccular dilation $> 100 \mu\text{m}$ of a retinal arterial vessel within the 1st three orders of bifurcation
- KEY FEATURES
 - Retinal hemorrhage (subretinal, intraretinal, preretinal, and vitreous)
 - “hourglass hemorrhage” highly specific
 - Protein and lipid exudation
 - Macular edema

Characteristics

- Commonly located in the temporal retina
- Leaking, telangiectatic vessels in the capillary bed that surrounds the macroaneurysm
- Retinal artery / vein occlusion
- In some cases significant visual morbidity results from macular hemorrhage, exudate, edema, or from the development of a vitreous hemorrhage

Ocular Manifestations

Hemorrhagic

- Acute loss of vision
- Subretinal, intraretinal, or preretinal hemorrhage
- Hemorrhage obscures aneurysm

Exudative

- Gradual decline in vision secondary to fluid/lipid accumulation in the macula

Epidemiology

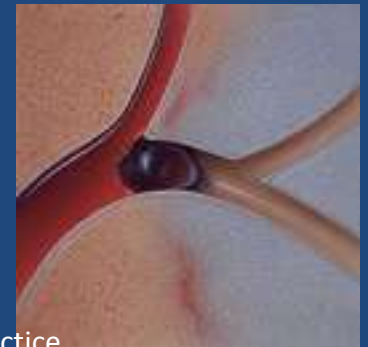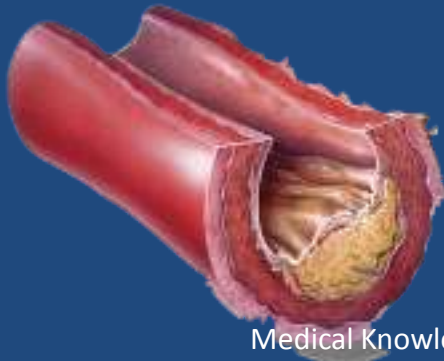
- > 60 years of age
- Female Preponderance 60%
- Usually unilateral but may be bilateral in less than 10% of cases
- The most consistent association is with HTN- a large controlled study reported HTN in 79% of patients.

Pathogenesis

Chronic HTN, along with the replacement of arterial smooth muscle by collagen may affect dilation of the arterial wall in an area of weakness or previous damage

RAM occur more frequently at AV crossings, because of the shared adventitial sheath which results in limited structural support

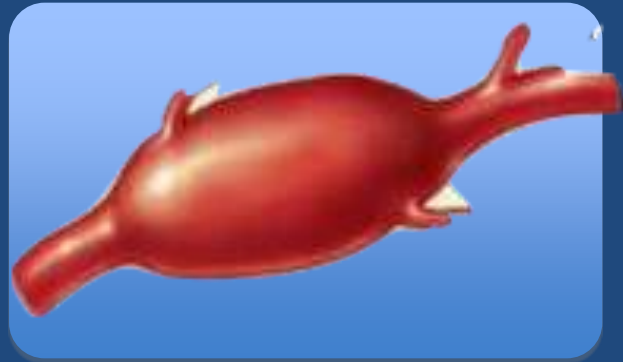RAM occur at sites of previously detected emboli. Focal arterial damage secondary to embolization can lead to aneurysm formation



Pathogenesis



Saccular Aneurysms (Blow out) are more likely to bleed possibly as a result of the thin, stretched, aneurysmal sac.



Fusiform Aneurysm are more prone to exudative changes and associated with venous occlusions.

Management/ Treatment

Observation

- This pt had macular involvement with metamorphopsia
- Toxic effect of large hemorrhage
- Often the possibility of spontaneous sclerosis

Photocoagulation

- Safe and effective
- Minimally invasive

YAG

- Controversial

Intravitreal Bevacizumab

- Risks outweigh the benefits


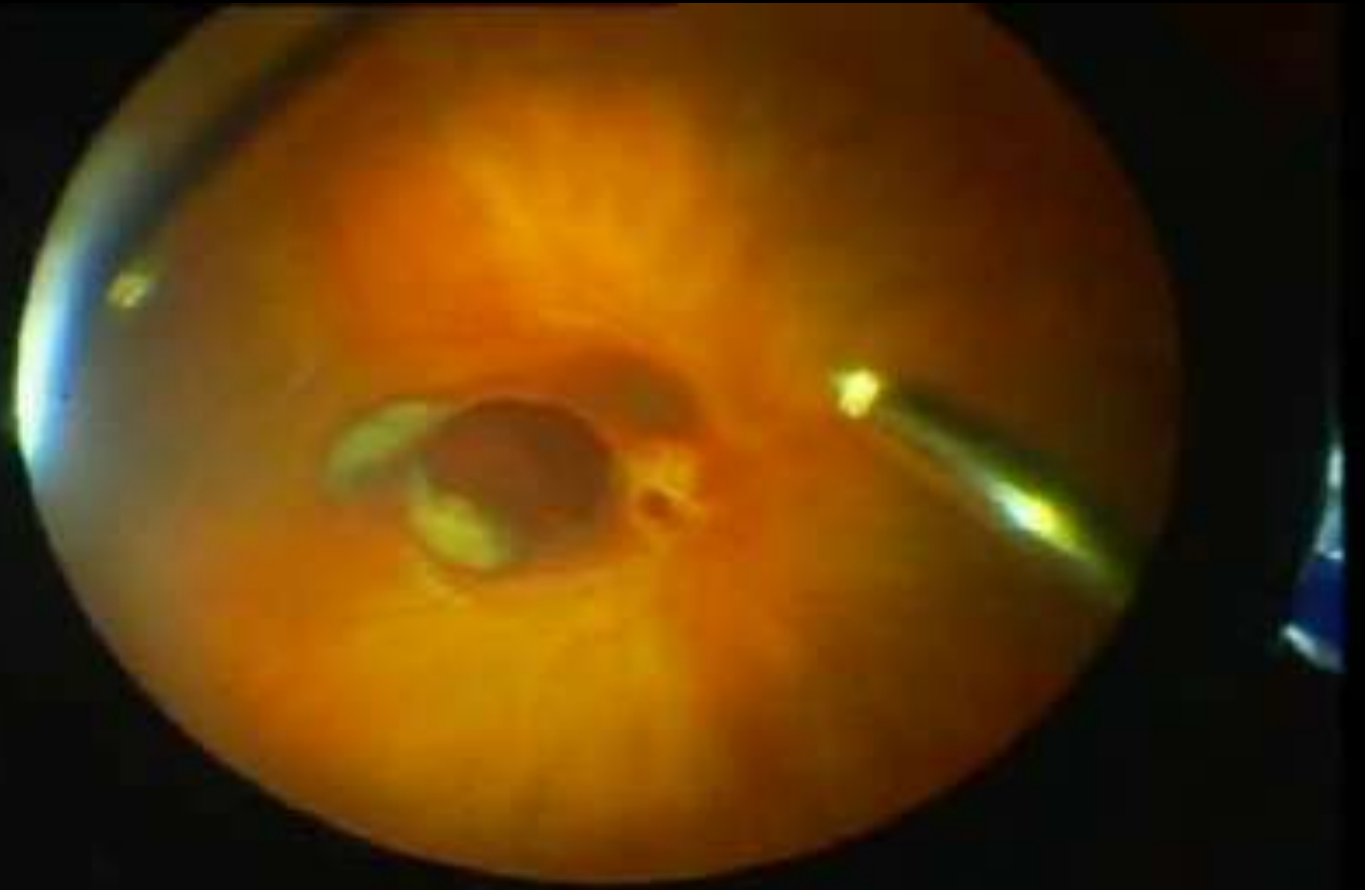
Vitrectomy

- No evidence of vitreous hemorrhage in this case
- VA at initial presentation was 20/20
- Risk outweigh the benefits

After treatment...

- Although arterial perforations may close, leaving the aneurysm intact, the lesion remains hemodynamically unstable & is predisposed to rebleed or transmission of fluid across its walls.
- Z shaped kinks develop spontaneously after aneurysmal rupture which may represent fibrotic changes in the media of the arterial wall causing traction on the adventitial portion in that segment, leading to shortening of the artery.
 - Z shaped kinks indicate a resolved and stable MA and does not require treatment.
- Possibility of Arterial & Venous occlusion

Bernd Kirchhof



Patient Care & Professionalism

Retinal arterial macroaneurysms: risk factors and natural history

Robert W Panton, Morton F Goldberg, Marilyn D Farber

Associations:

- Decreased VA ($p < 0.001$)
- Hypertension ($p = 0.037$)
- Female gender ($p = 0.099$)
- Retinal vein occlusions ($p = 0.055$)

Observations:

- Retinal hemorrhage (81%)
- Retinal exudate (70%)
- Vitreous hemorrhage (30%)
- Macular involvement (30%)
- Arteriolar narrowing (26%)
- Arteriolar occlusion after laser (16%)

ND-YAG LASER APPLICATION IN PREMACULAR SUBHYALOID HEMORRHAGE

Mehdi Nili-Ahmadabadi MD^{*}, Ali-Reza Lashay MD, Reza Karkhaneh MD, Masood-Reza Manaviat MD, Ali Amini MD, Adel Razaghi MD, Zahra Alami MD

- Case-series: 12 eyes with premacular subhyaloid heme
- Hyaloidotomy was successful in 100% of the pts & the trapped blood was released into the vitreous cavity and absorbed within 6 to 16 days. The range of preoperative visual acuity was HM to CF at 3 meters which improved from 20/50 to 20/20 postoperatively.
- Posterior hyaloidotomy by Nd-YAG laser is an outpt procedure which may obviate the need for more complex surgical interventions.

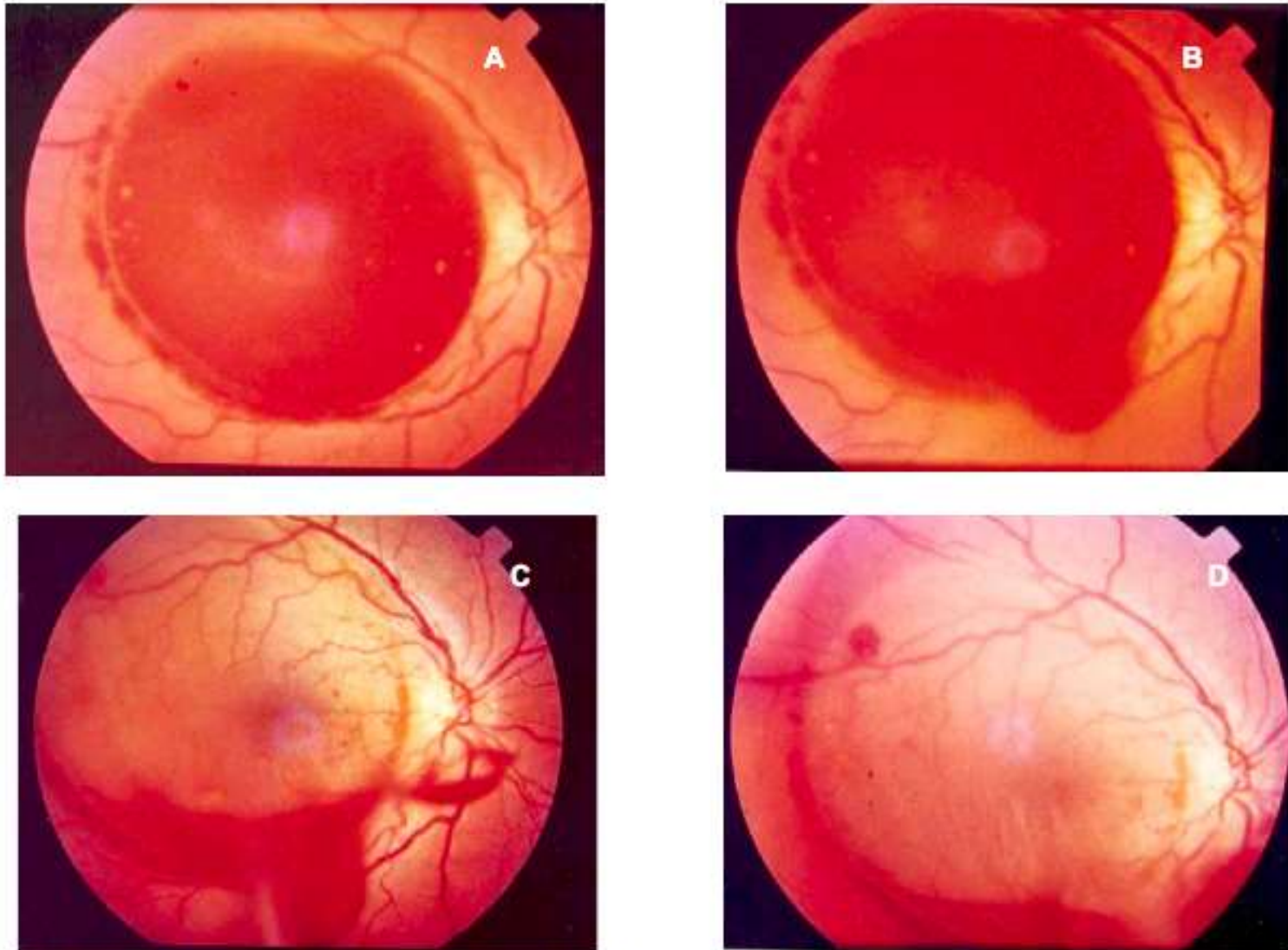


Figure 1. (A) Before laser, (B) four minutes after laser, (C) five days after laser (absorption was incomplete), and(D) nine days after laser.

Management of ruptured retinal arterial macroaneurysm with intravitreal bevacizumab.

Javey G, Moshfeghi AN, Moshfeghi AA.

Bascom Palmer Eye Institute, Department of Ophthalmology, University of Miami Miller School of Medicine, Palm Beach Gardens, Florida 33418 , USA.

- 79-yo F p/w a h/x of HTN & a ruptured RAM with pre-retinal, intraretinal, & subretinal hemorrhages extending into the macula. VA at presentation was **20/400**. The pt was treated w/ 2 intravitreal injections of bevacizumab at 4-wk intervals. Steady clearing of the hemorrhages was observed with restoration of final VA to **20/20** in the 12 months after the initial presentation
 - the novel application of intravitreal bevacizumab may be used in the tx of ruptured RAM

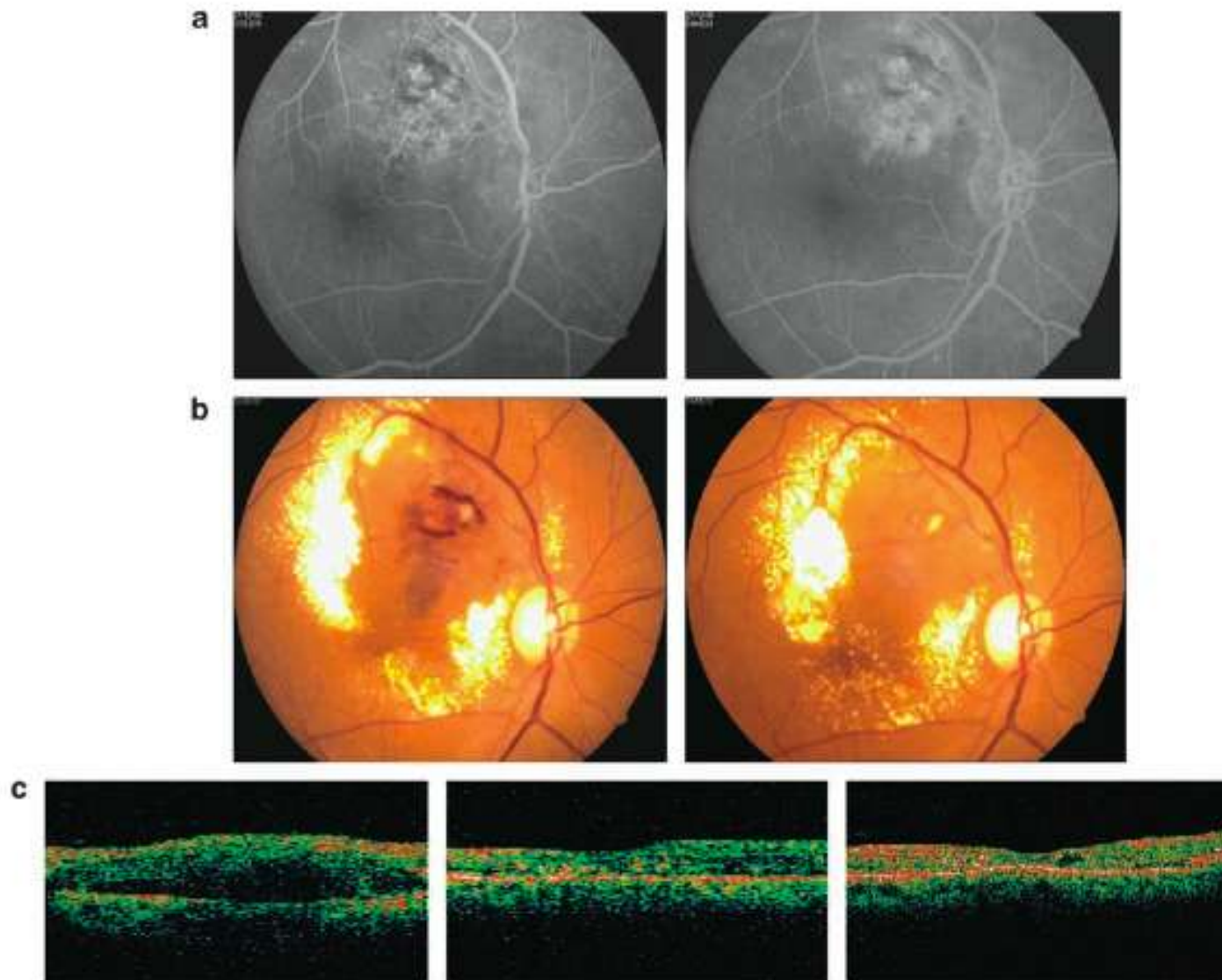
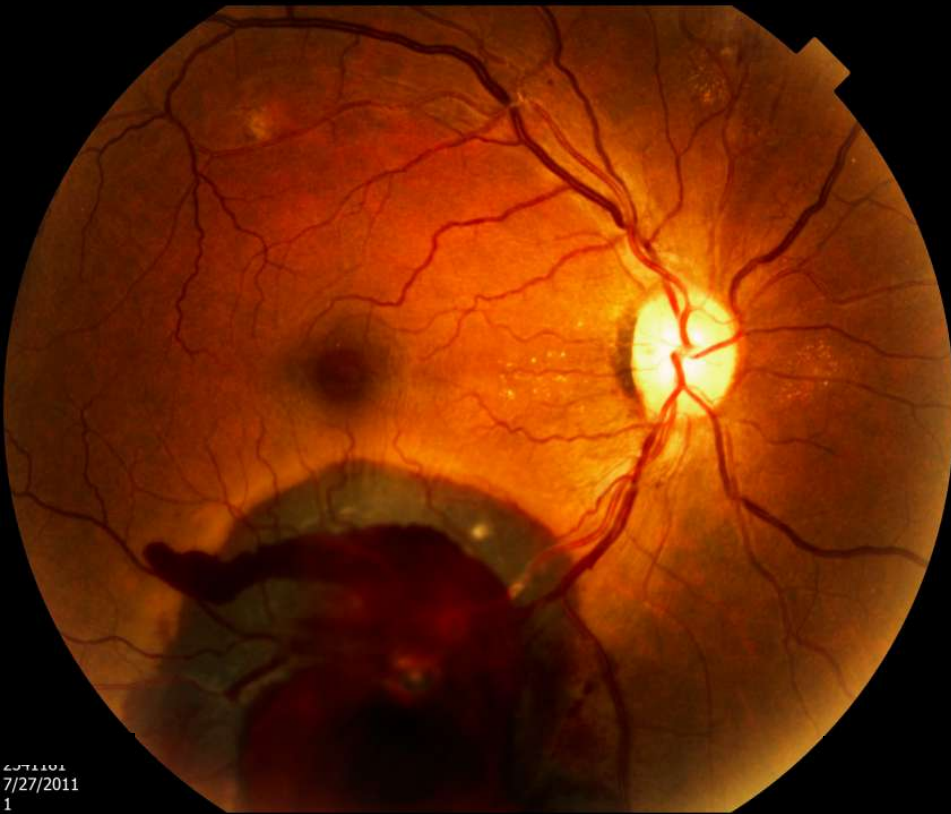

Figure 1 (a) Fluorescein angiogram showing hypofluorescence from blockage due to retinal haemorrhages and a hyperfluorescent retinal macroaneurysm with leakage of dye in late phase. (b) Fundus photograph showing retinal macroaneurysm along superotemporal retinal arteriole associated with retinal hemorrhages, lipid exudation and macular edema (left). Post bevacizumab injection fundus picture showing resolved retinal hemorrhages and decrease in lipid exudation and macular edema (right). (c) Retinal thickness measured by optical coherence tomography at baseline (607 μ m; left), after 4 weeks (271 μ m; middle), and after 6 weeks (173 μ m; right).

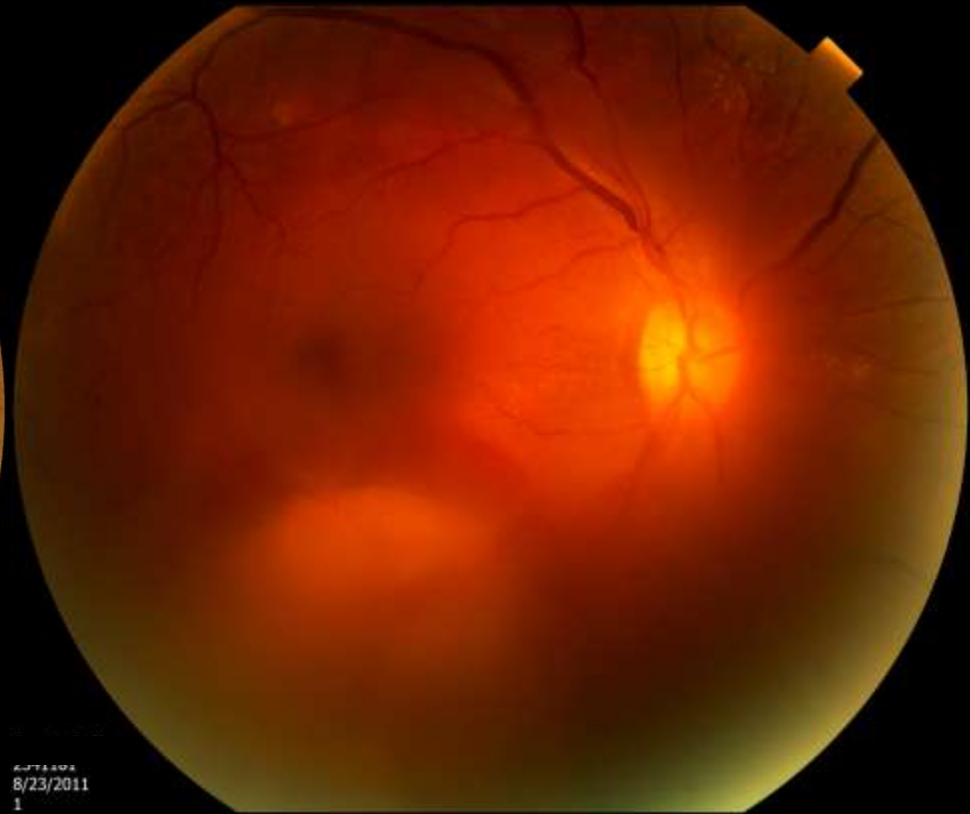Our patient

- CTA & CT head wnl
- The pt was admitted & given several blood pressure (bp) lowering agents with normalization of bp
- Focal Laser OD to stimulate closure of the macroaneurysm
 - Power: 270 mW; Size: 310 um; Time: 0.10 sec; Ct: 14 shots
- The pt tolerated the procedure well & was discharged with bp lowering meds & medical f/up

Fundus photos at presentation & one month after focal laser



VA 20/20



VA 20/20

Self Reflective Practices

- This case was managed appropriately. In cases such as this one, rapid and correct diagnosis is very important as subretinal heme is toxic and causes severe and irreversible damage to the retina. Our patient was accurately diagnosed in a timely manner and the pt received prompt intervention.
- This case exemplifies the importance of the role of the ophthalmologist in helping patients to maintain general health.

Core Competencies

- **Patient Care**- provide patient care that is compassionate, appropriate, and effective for the treatment of health problems and the promotion of health.
- **Medical Knowledge**- demonstrate knowledge of established and evolving biomedical, clinical, epidemiologic and social and behavioral sciences, as well as the application of this knowledge to patient care.
- **Practice-based Learning and Improvement**- demonstrate the ability to investigate and evaluate the care of patients, to appraise and assimilate scientific evidence, and to continuously improve patient care based on constant self-evaluation and life-long learning.
- **Interpersonal and Communication Skills**- demonstrate interpersonal and communication skills that result in the effective exchange of information and collaboration with patients, their families, and health professionals.
- **Professionalism**- demonstrate a commitment to carrying out professional responsibilities and an adherence to ethical principles.
- **Systems-based Practice**- demonstrate an awareness of and responsiveness to the larger context and system of health care, as well as the ability to call effectively on other resources in the system to provide optimal health care.

References

- G Javey et al. Management of ruptured retinal arterial macroaneurysm with intravitral bevacizumab. *Ophthalmic Surg Lasers Imaging*. 2010; 41 (4); 1-5.
- M Ahmadabadi et al. Nd- Yag Laser Application in Premacular Subhyaloid Hemorrhage. *Archives of Iranian Medicine*. 2004; 7 (3)
- *Ophthalmology* by Myron Yanoff & Jay S. Ducker
- W Townsend-Pico, S Meyers, H Lewis. Indocyanine Green Angiography in the Diagnosis of Retinal Arterial Macroaneurysms Associated with Submacular & Premacular Hemorrhages: A Case Series. *Am J Ophthal*. 2000; 129 (1) 33-7; 206-9.
- M Khalek and J Richardson. Retinal Macroaneurysm: natural history and guidelines for treatment. *Br J Ophthalmol*. 1986; 70(1): 2-11.
- American Academy of Ophthalmology. Basic Clinical Science Course. Retina & Vitreous; Section 12.

Thank you

- Our Patient
- Dr. Olumba
- Dr. Fletcher
- Dr. Schaab
- Dr. Sobel
- Dr. Narang
- Dr. Calderon