

Ophthalmology Grand Rounds

David Rand, MD

SUNY Downstate Medical Center

November 1, 2012

History

- 79-yr-old Caucasian man presented to outpatient clinic for routine dilated fundus examination
- Pt reported no vision changes and had no ocular complaints since last routine visit 6 months prior
- PMHx: HTN
- POHx: Denies, no Hx of surgery or trauma
- FamHx: No Hx glc/blindness
- SocialHx: + Hx of smoking years ago
- Meds: Vitamin C, no drops
- Allergies: NKDA

Examination

- dVAcc glasses 20/20 OU
- EOM full OU
- CVF full OU
- Pupils pharm dilated OU
- Tap WNL OU
- SLE

LLA mgd OU

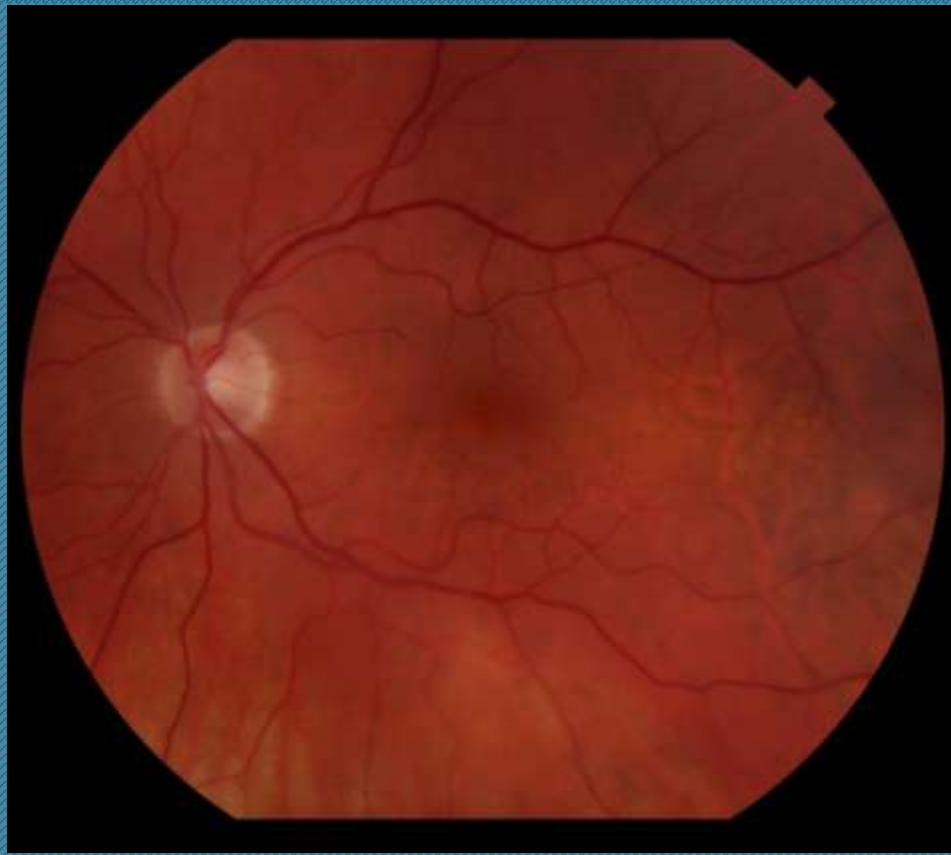
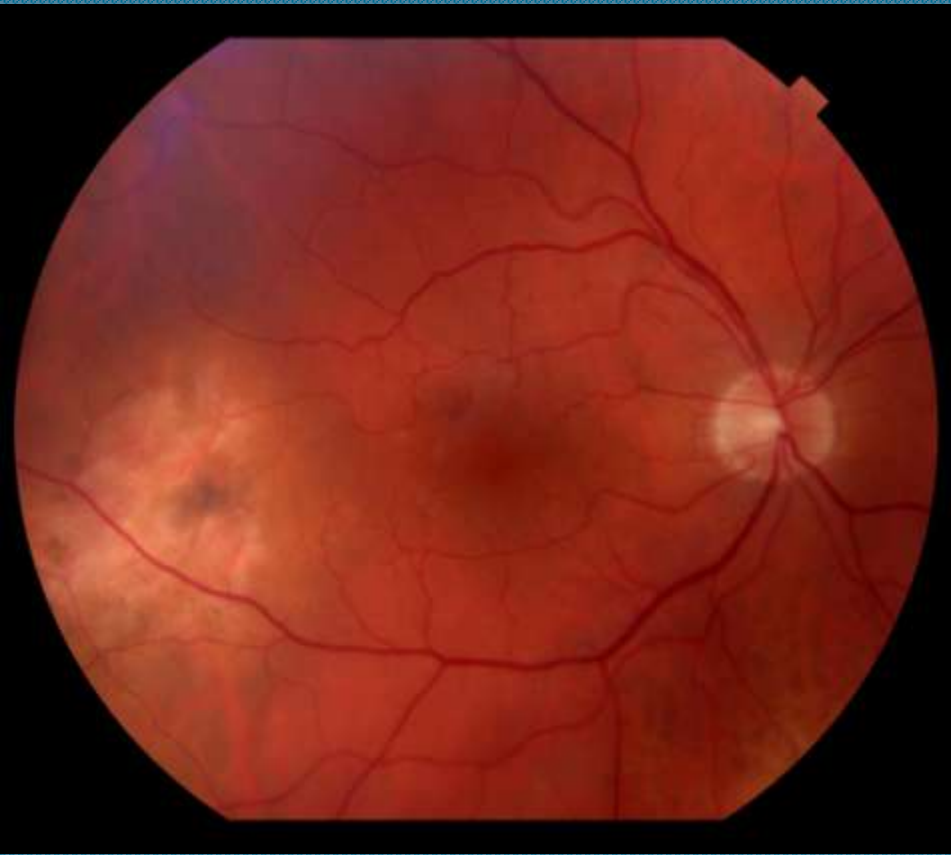
CS w/q OU

K clear OU

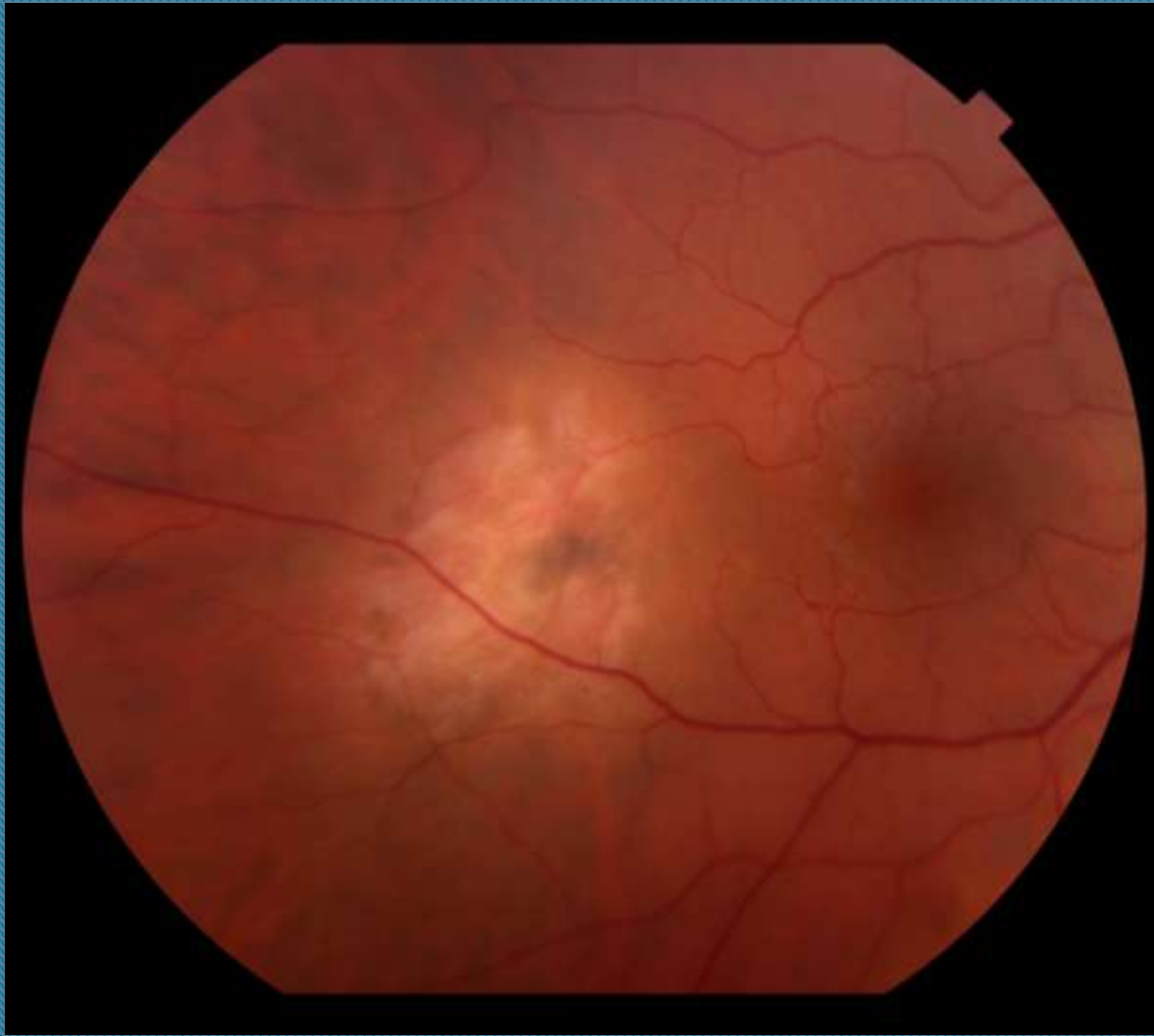AC d/q OU

IP r/r OU, no NVI appreciated OU

L 1+ NS OU



Courtesy of Dr. Paul Finger

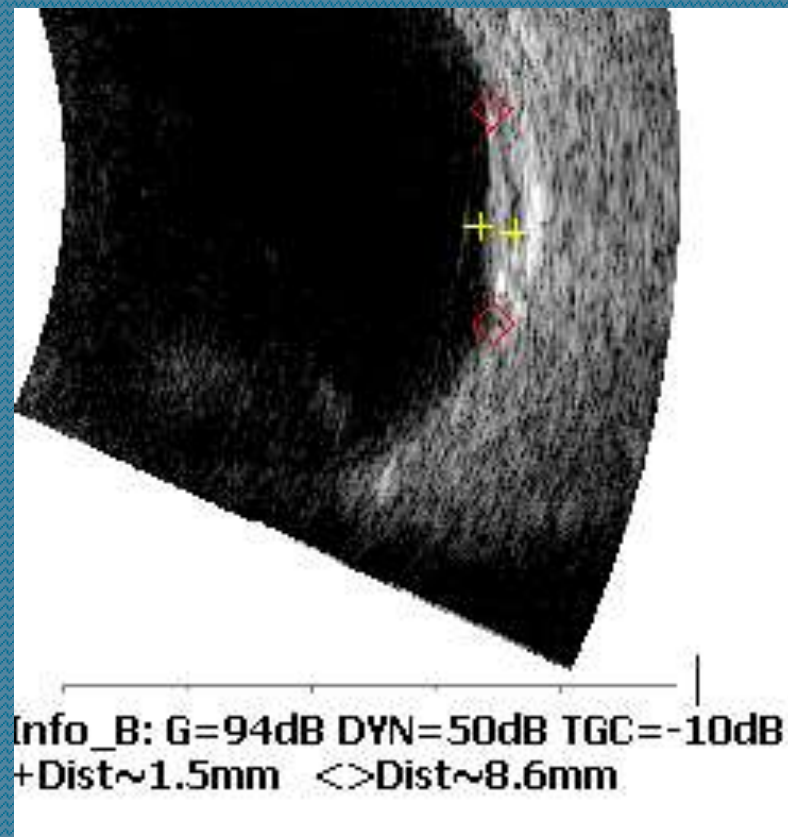
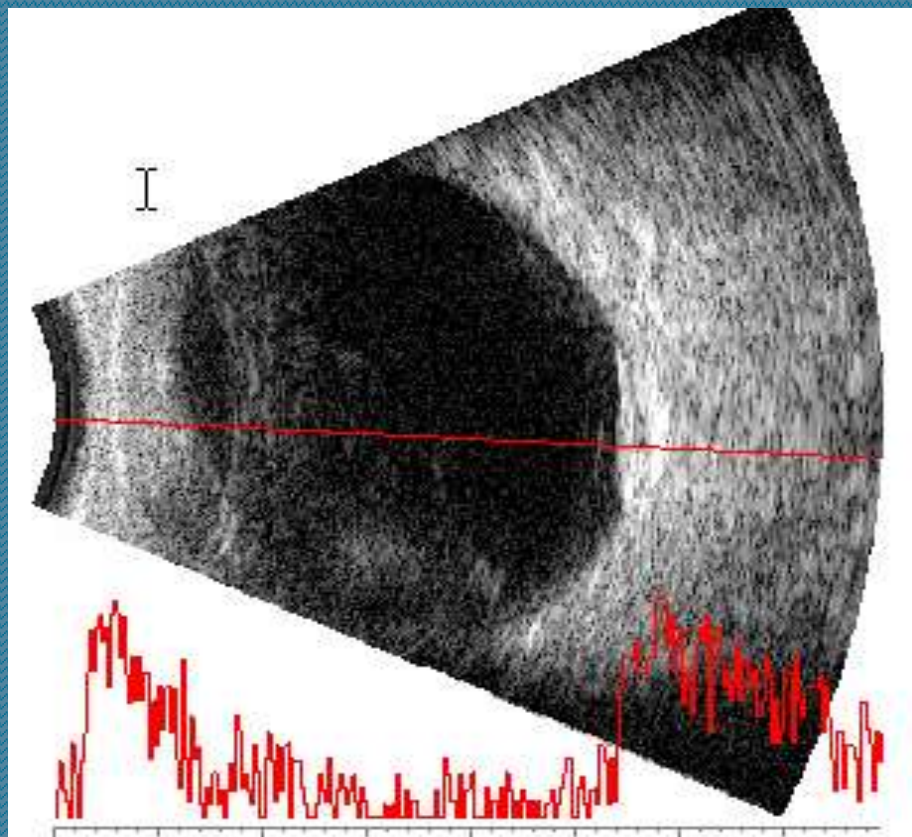


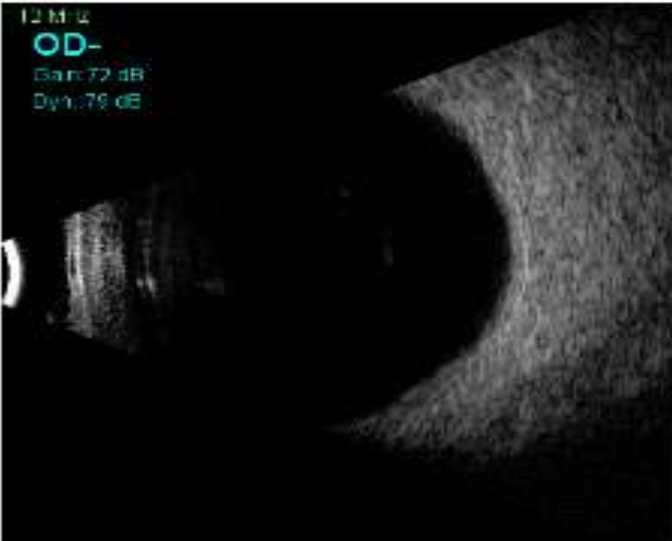
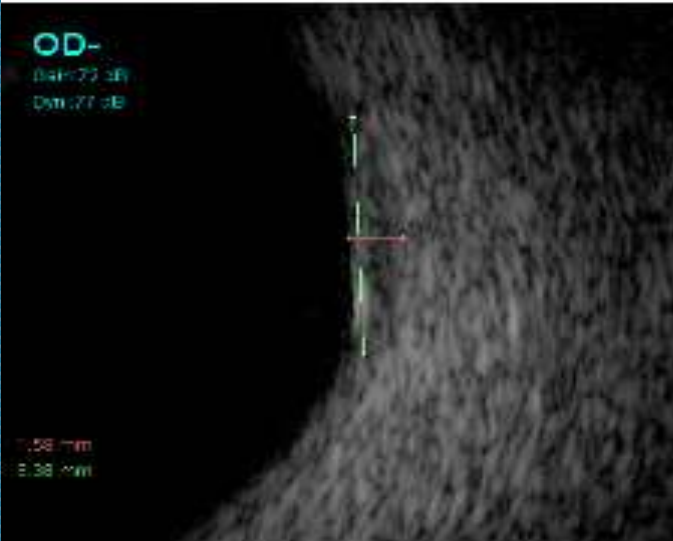
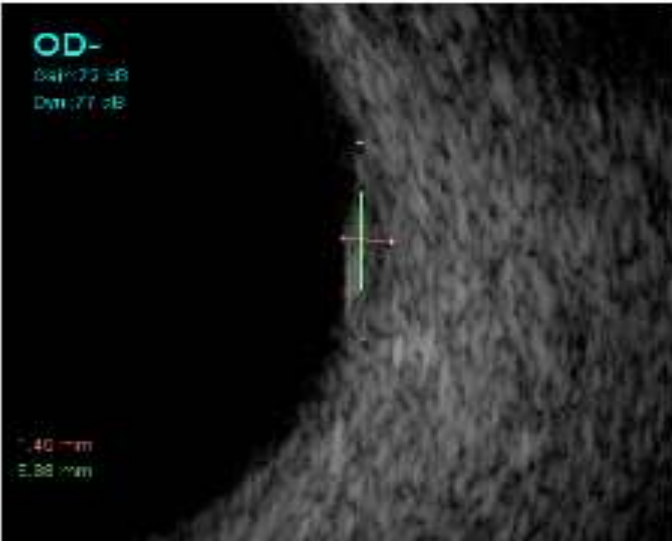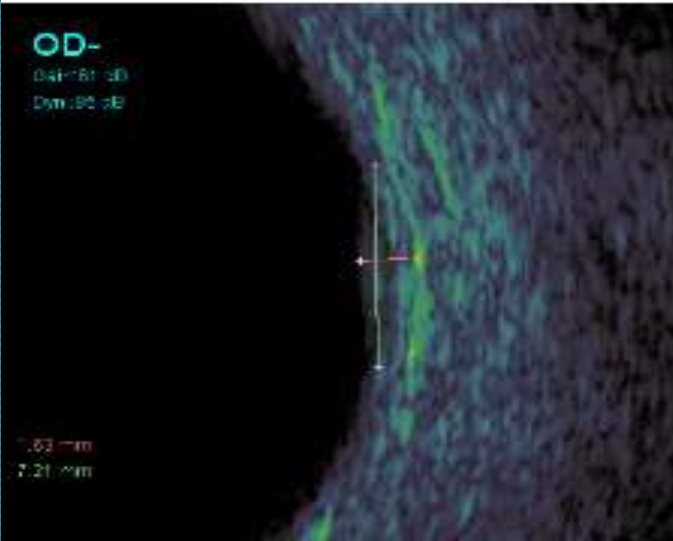
Courtesy of Dr. Paul Finger

Examination

- DFE
- V clear OU
- M flat OU
- CD 0.4/0.4, s/p OU
- V mild attenuation OU
- P temporal choroidal lesion approx 5-6 disc areas, slightly elevated, heterogeneously pigmented, no orange pigment, peripheral drusen, no clinically-apparent sub-retinal fluid OD, otherwise no evidence of detachment, hole, or tear OU

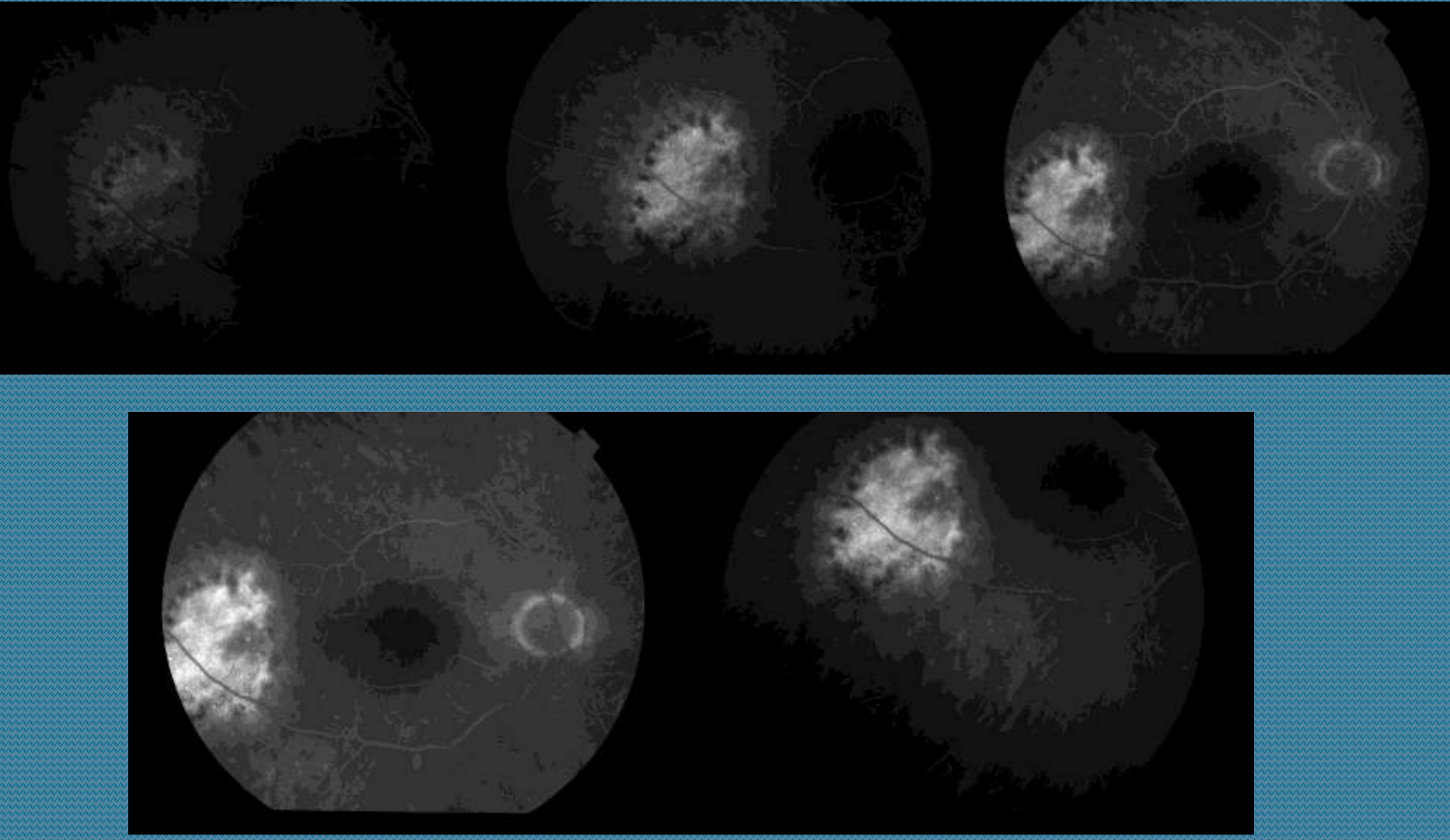
B-Scan





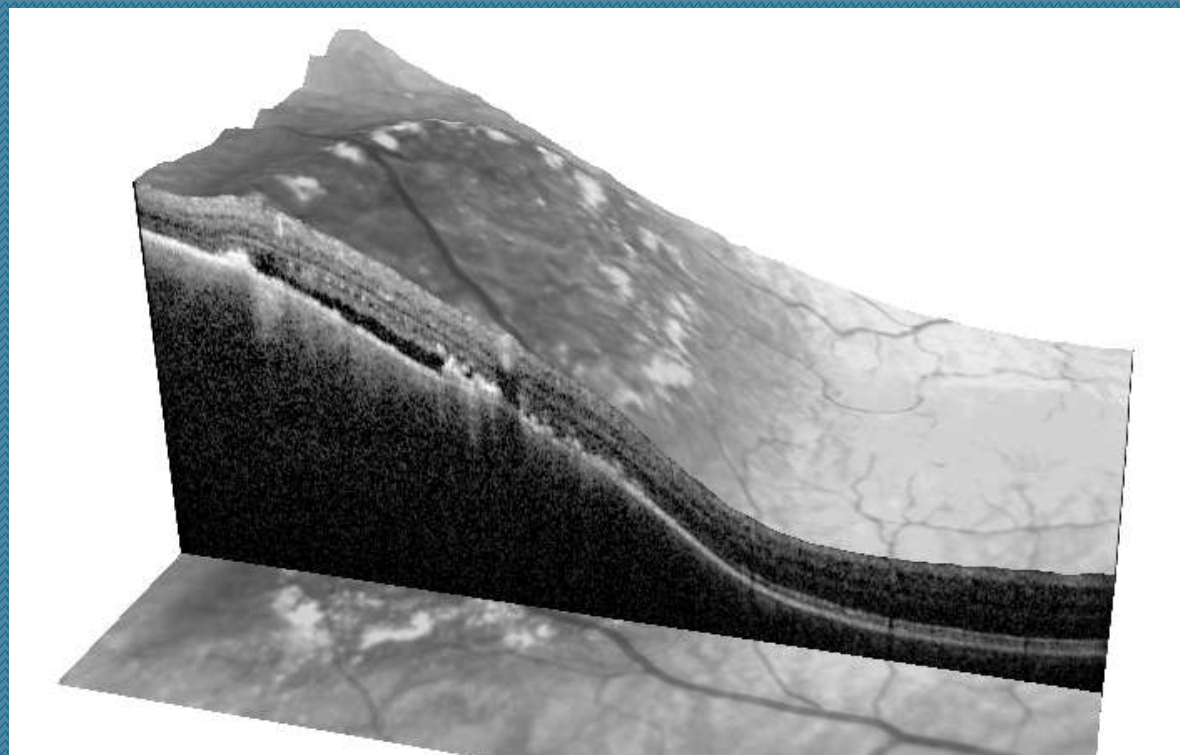
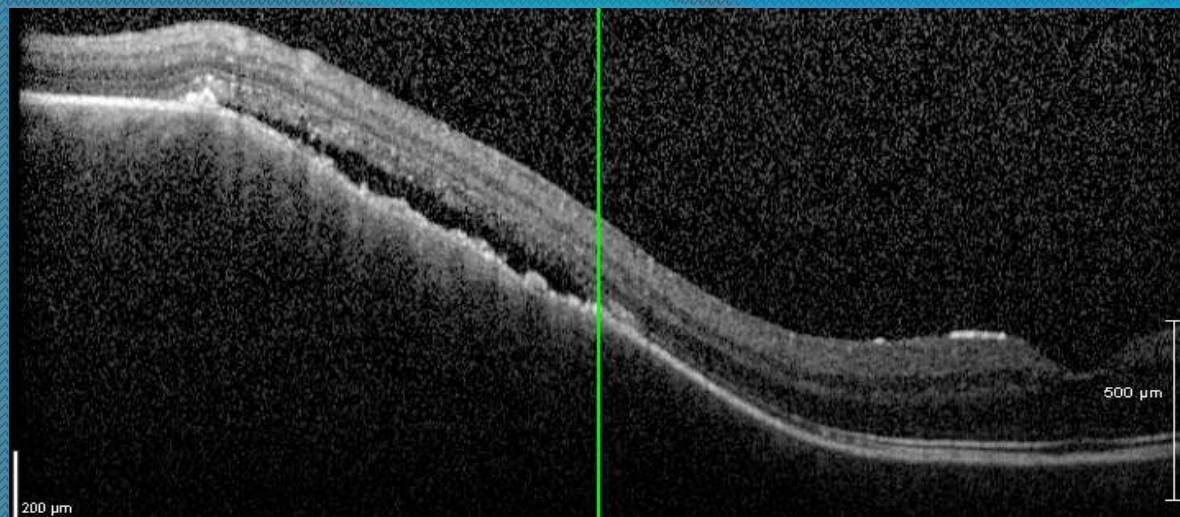
Comments:
B-scan: 12 MHz Ultrasound Imaging

FA

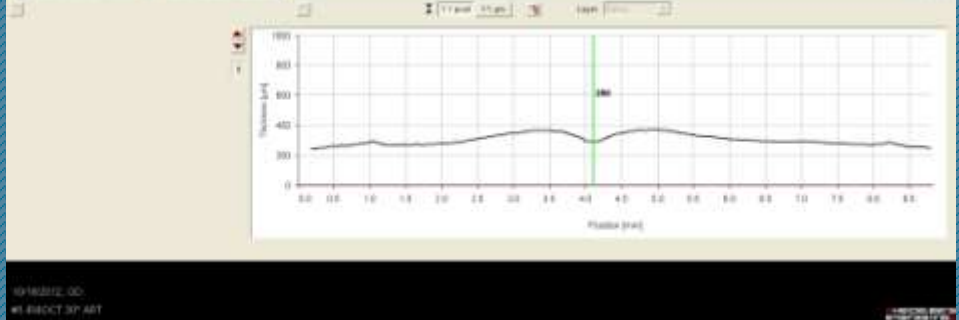
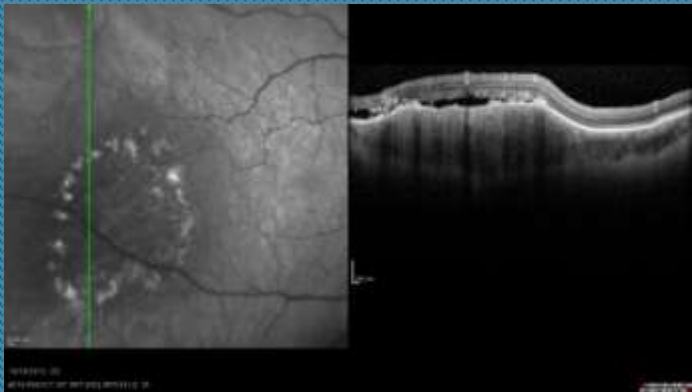
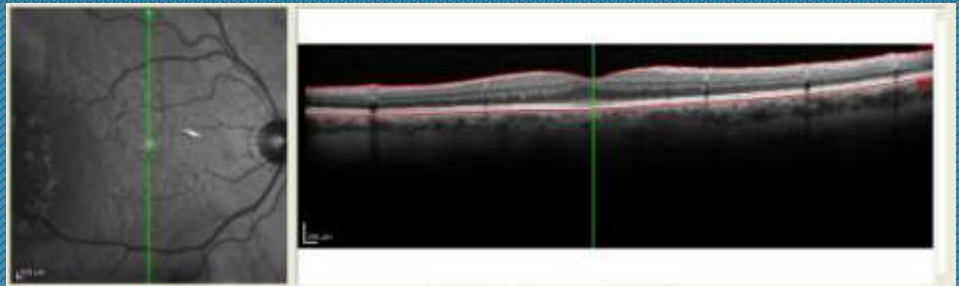
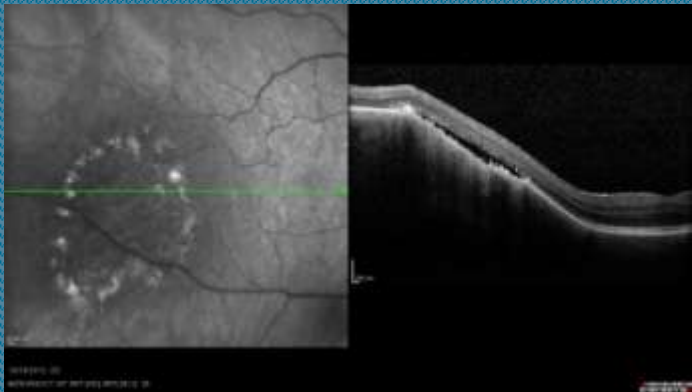
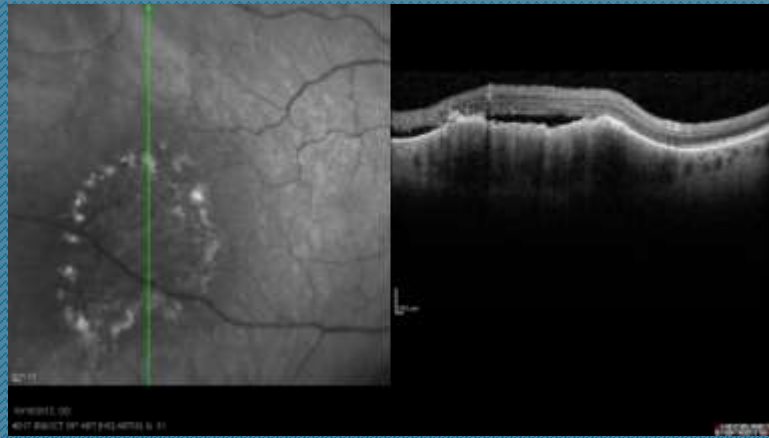
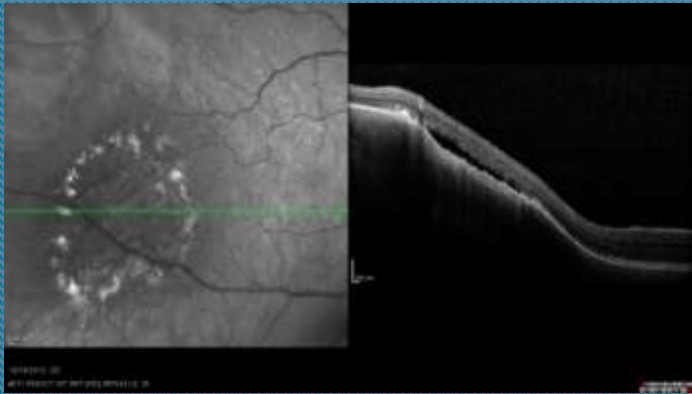


Courtesy of Dr. Paul Finger

OCT



OCT



Courtesy of Dr. Paul Finger

Differential Diagnosis?

Patient Care, Medical Knowledge, Practice-based
Learning and Improvement

Differential Diagnosis

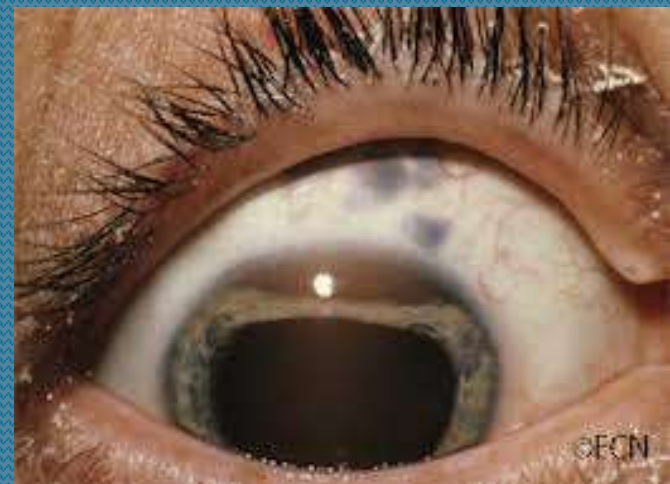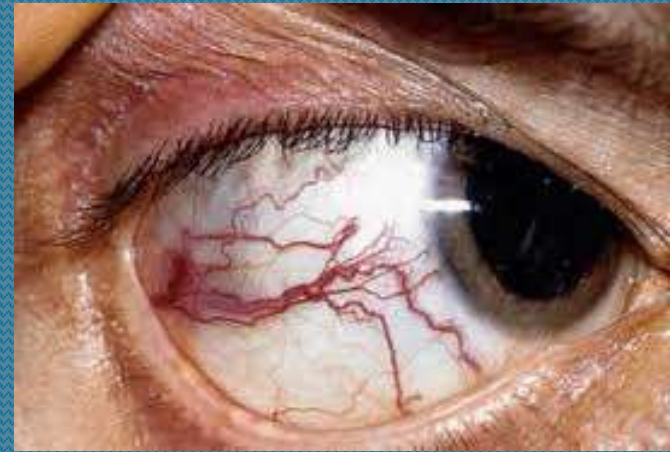
- Choroidal melanoma
- Choroidal nevus
- Metastatic lesion
- Congenital hypertrophy of the RPE (CHRPE)
- Reactive hyperplasia of the RPE
- ARMD
- Melanocytoma
- Choroidal detachment/localized suprachoroidal hemorrhage
- Circumscribed choroidal hemangioma
- Nodular posterior scleritis
- Choroidal osteoma
- Ocular melanocytosis
- Massive gliosis of retina

Choroidal/Ciliary Body Melanoma

- Most common primary intraocular malignancy in adults
- Incidence in the United States approximately 6 cases per million
- Rare in children, primarily affects patients between 50 and 70 years old
- Most commonly in Caucasian or other lightly-pigmented individuals
- Ocular melanocytic lesions such as ocular and oculodermal melanocytosis (nevus of Ota) have been shown to be risk factors for development of choroidal melanoma

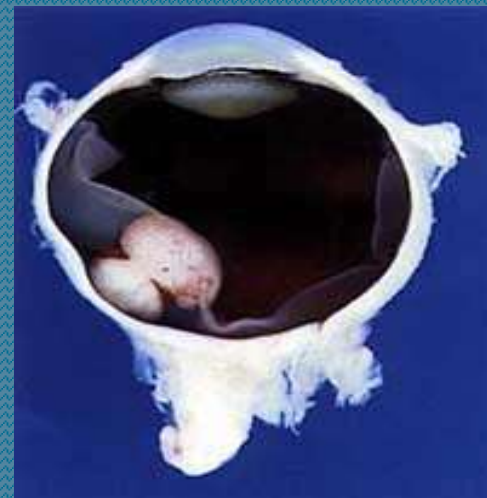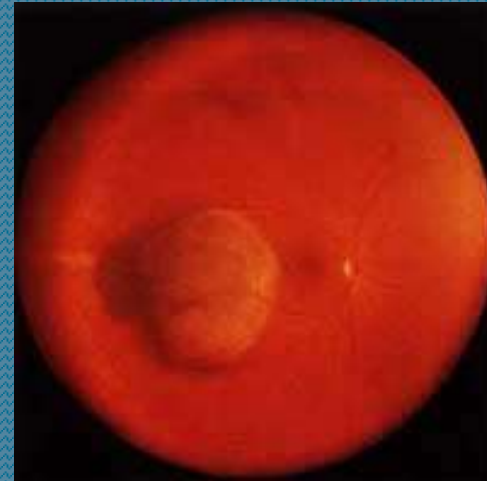
Choroidal/Ciliary Body Melanoma

- Although some melanomas are detected on ophthalmic evaluations prompted by visual symptoms (i.e. blurred vision, field defect, flashes, floaters), many patients are asymptomatic
- Usually no pain; rarely pain as a result of secondary glaucoma or tumor necrosis
- Virtually all ciliary body melanomas stimulate development of dilated episcleral sentinel vessels; some extend through sclera to form epibulbar nodule(s)



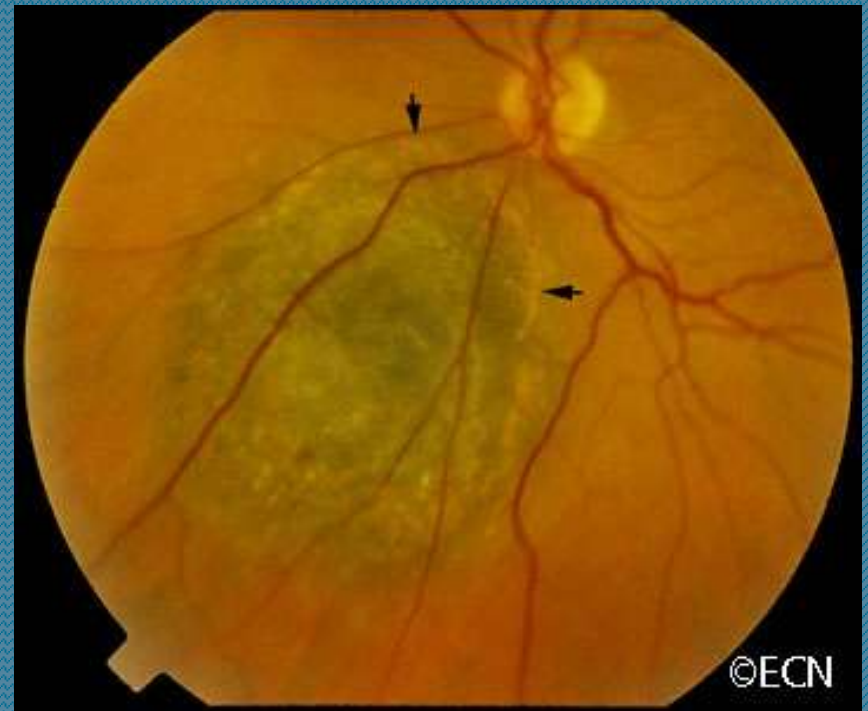
Ocular Manifestations

- Typically solid, dark brown to golden tumor
- Nodular, elevated
- Biconvex, lenticular cross-sectional shape
- About 20% eventually break through Bruch's membrane and RPE to form nodular eruption beneath retina
- Enlargement of this eruption may take on mushroom-like configuration—highly characteristic but not pathognomonic



Ocular Manifestations

- Small, darkly-pigmented lesions may exhibit clumps of orange lipofuscin pigment on the surface—more likely malignant
- Secondary nonrhegmatogenous retinal detachment—clear, serous, shifting subretinal fluid
- Fluid may exist only over base of tumor or may accumulate to extent that retina is totally detached
- Fluid may contain blood (particularly in tumors that rupture Bruch's membrane)
- Vitreous hemorrhage may be presenting manifestation if retinal invasion
- If large enough may indent equatorial region of lens

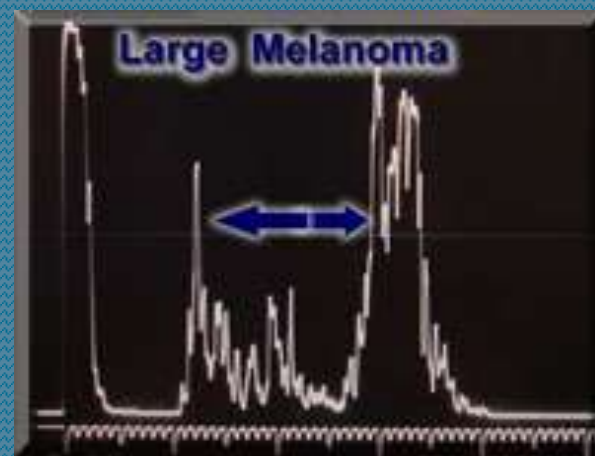
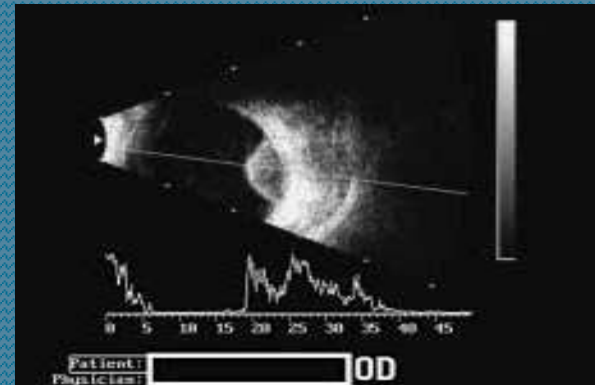


Risk Factors for Malignancy

- Thickness > 2 mm
- Subretinal fluid
- Presence of symptoms
- Prominent orange pigment over the lesion
- Location < 3mm from the optic disc
- Mushroom shape with congested blood vessels in the dome of the tumor
- Growth

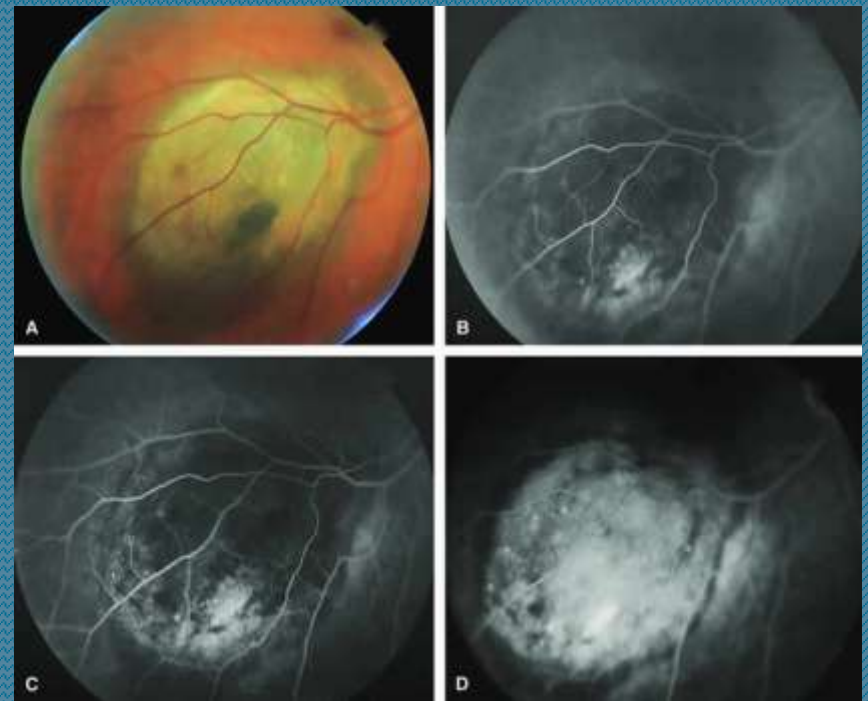
Diagnosis

- B-scan: solid, acoustically dark (relative internal sonolucency in basal aspect), although cap acoustically bright
- Examine for choroidal excavation
- A-scan: low-amplitude internal reflectivity, stepwise decremental reduction in echo spike from front to back of lesion; fluctuations in height of intralesional echoes coincident with pulse are indicative of intralesional blood vessels



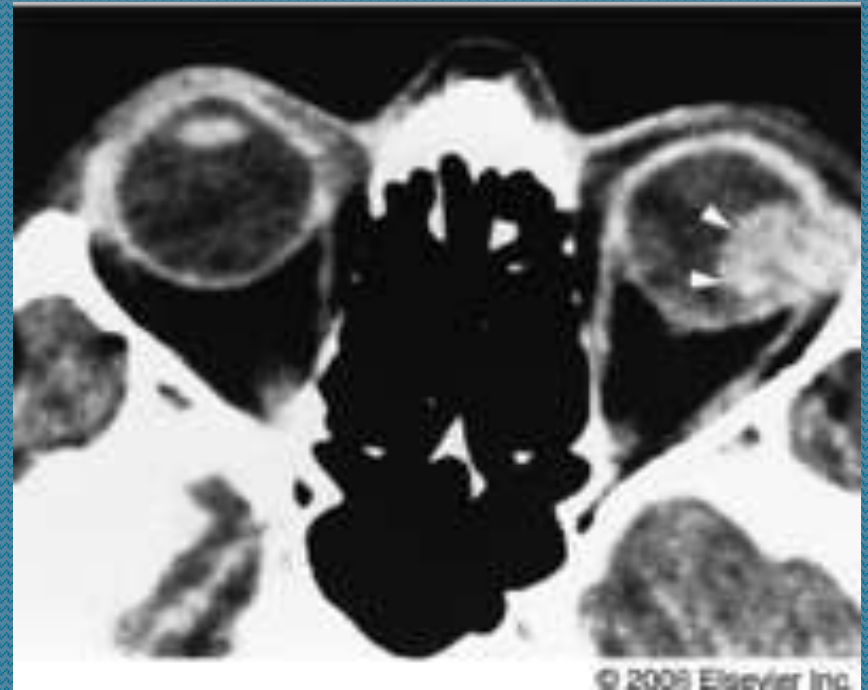Diagnosis

- FA: several distinct patterns dependent on cross-sectional tumor shape, tumor pigmentation, health of overlying RPE, and extent of invasion
- Typical melanoma with intact Bruch's membrane:
 - hypofluorescent in early stages
 - few large-caliber intralesional vessels detected in early phase, will become ill-defined within a few seconds due to diffuse leakage of fluorescein into extracellular space of tumor
 - in late phases tumor and subretinal fluid stain intensely
- If Bruch's membrane compromised, prominent apical intralesional blood vessels fill slowly but leak intensely during the study
- Retinal invasion: retinal vessels at area of invasion may be masked (hypofluorescent) by pigmented tumor cells ; small retinal vessels at margins leak as well in late stages
- ICG: usually tumors are hypofluorescent throughout the study



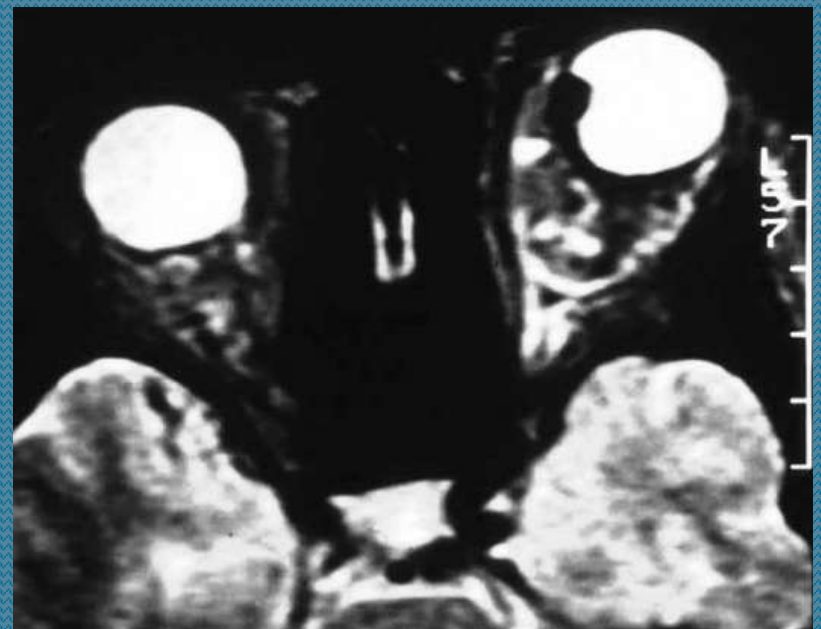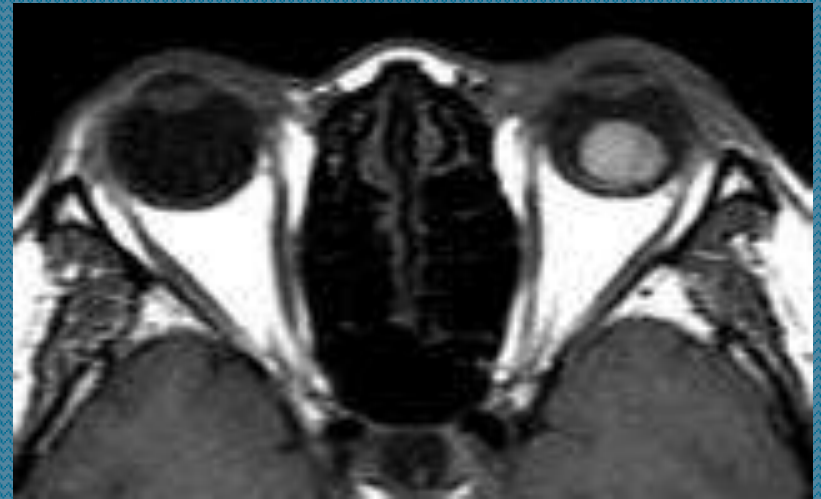Diagnosis

- CT: capable of imaging most melanomas
- Virtually all melanomas (except those that are totally necrotic) exhibit significant contrast enhancement, but this feature is present in all intraocular tumors
- Subretinal fluid appears isodense with tumor



Diagnosis

- MRI: Tumor appears hyperintense compared to dark vitreous on T1-weighted imaging and hypointense compared to bright vitreous on T2-weighted imaging
- More specific pattern for choroidal melanoma than CT
- May detect posterior extrascleral tumor invasion

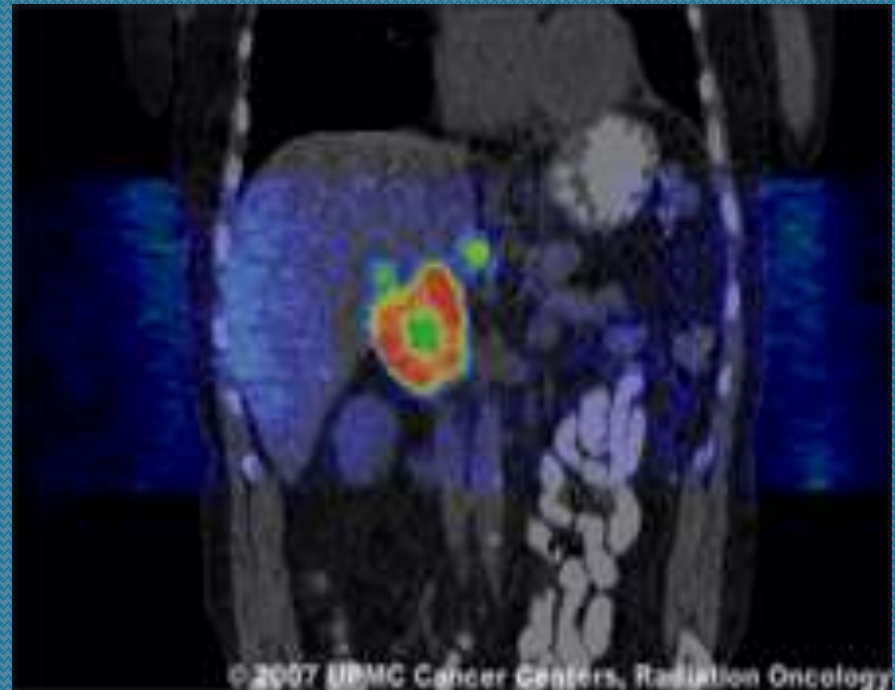


Diagnosis

- Open surgical biopsy: unless aim is to achieve total tumor resection, not advised, as it is associated with high rates of local recurrence and death from metastatic disease
- Fine needle aspiration biopsy may be safer (even though few melanoma cells in scleral needle track documented pathologically)

Baseline Systemic Evaluation

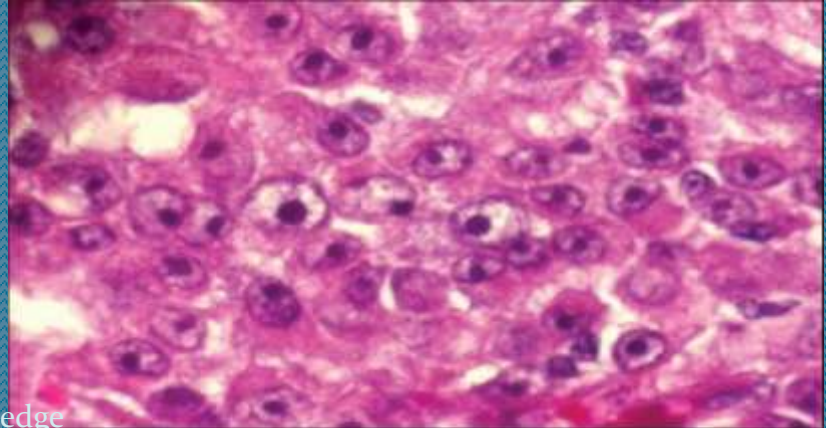
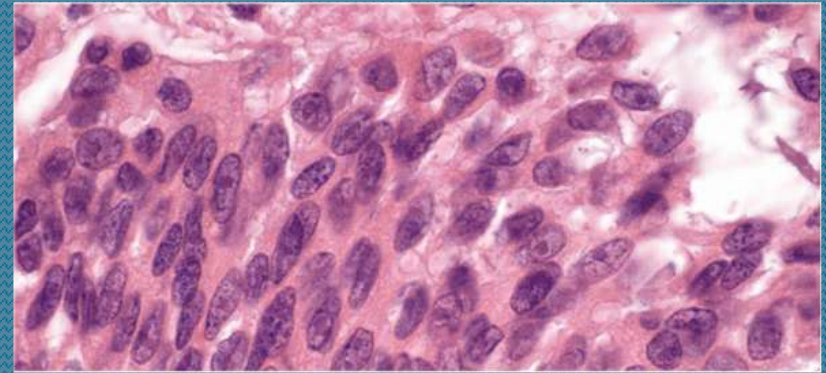
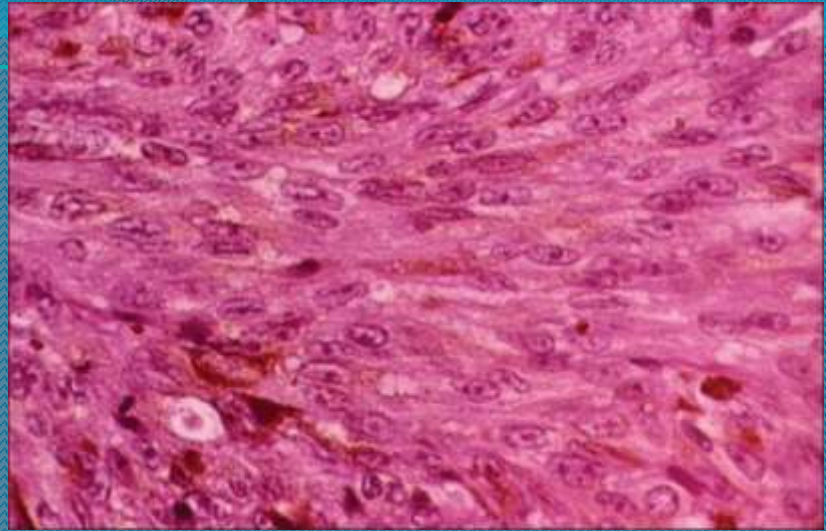
- Complete physical examination
- Selected blood tests: CBC, liver enzymes
- CXR
- CT, MRI, and/or U/S of abdominal organs
- Some centers are using PET/CT scans for baseline systemic evaluation
- 98% of patients have no detectable systemic disease at time of diagnosis
- Those with systemic metastases usually have a large tumor with extrascleral invasion



© 2007 M.D. Anderson Cancer Center, Radiation Oncology

Pathology

- All uveal melanomas are composed of anaplastic melanocytic cells with relatively large nuclear-to-cytoplasmic ratio and 1 or more prominent nucleoli
- Most have relatively frequent mitotic figures
- Less pronounced anaplasia: spindle cells
- More anaplasia: epithelioid cells
- Modified Callender classification as spindle cell, mixed, or epithelioid
- If cells necrotic, cannot note classification of cell type
- Spindle cell: best prognosis
- Mixed: intermediate
- Epithelioid: worse prognosis



Prognostic Factors

- Size of largest tumor dimension in contact with sclera
- Cell type of tumor
- Mean of the 10 largest cell nuclei (MLN)
- Vascular closed loops or vascular networks (3 loops back-to-back) associated with increased incidence of subsequent metastases
- Cytogenetic abnormalities such as monosomy 3 have increased risk of metastasis
- Iris melanoma better prognosis
- Diffuse ciliary body melanomas (ring melanoma) particularly poor prognosis although usually mixed-cell type

Complications

- Metastases—usually hematogenous spread. More than 95% of deaths have liver involvement; in as many as 1/3 of deaths, liver is sole site of metastasis
- Serous detachments
- Intraocular inflammation
- Secondary glaucoma—also tumor necrosis may lead to liberation of melanin pigment into angle causing *melanomalytic glaucoma*

Treatment

- Many therapeutic options available
- Dependent on size of tumor, location, extent of tumor invasion, and presence or absence of extrascleral extension or distant metastases
- Must consider visual status of affected/fellow eye, general health of patient, and personal preference of patient

Collaborative Ocular Melanoma Study (COMS)

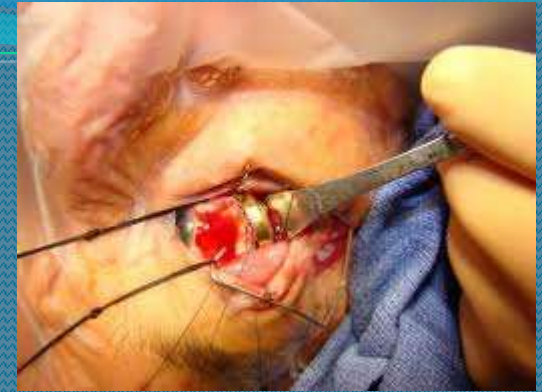- Multicenter trial
- Comparison of enucleation versus radiation for tumors at least 2.5 mm but no more than 10 mm in height and no more than 16 mm in basal diameter
- Comparison of standard enucleation versus enucleation preceded by external beam radiation for tumors greater than 10 mm in height or greater than 2 mm in height and greater than 16 mm in basal diameter or greater than 8 mm in height if there is optic nerve involvement
- Study outcomes: comparison of all-cause mortality, cancer-free and metastasis-free survival, and years of useful vision in affected and fellow eye

Enucleation

- To rid the body of the cancer
- Usually performed for large tumors in eyes that are painful and with affected vision
- Commonly performed for ciliary body or choroidal melanoma
- Good cosmetic result with prosthesis
- However, there is a suggestion (Zimmerman hypothesis) that enucleation may worsen survival prognosis
- Especially if trans-scleral extension has occurred, pre-enucleation adjuvant radiation therapy may lessen recurrence rate in the anophthalmic orbit
- However, Collaborative Ocular Melanoma Study did not show a survival benefit compared to enucleation alone
- Even if no detectable distant metastases, tumor cells are regularly disseminated—half of all patients treated with enucleation eventually die of metastatic melanoma

Radiation Therapy

- Most commonly employed therapeutic method
- Plaque radiotherapy or proton beam radiation
- Plaque radiotherapy: radioactive plaque (ruthenium-106 or iodine-125) sutured to episcleral surface directly exterior to tumor, removed 3-5 days later
- Proton beam radiation: Surgical localization of tumor base, suturing of radiopaque markers (tantalum rings) to sclera around tumor base, computer-based simulation of treatment, and finally treatment with charged particle beam while direction of gaze is maintained. Treatment 4-5 sessions over 4-7 days
- Gamma knife radiotherapy and stereotactic radiosurgery alternative options—no long term results available
- COMS study: plaque therapy equivalent to enucleation for survival
- Other studies: plaque and proton beam therapy equal to enucleation for survival



Radiation Complications

- Usually with treatment vision remains stable or slowly improves
- However, vision loss secondary to radiation retinopathy, optic papillopathy, or neovascular glaucoma may occur
- Pain secondary to ocular ischemia or neovascular glaucoma
- 10-15% of patients treated with plaque therapy and 3-5% treated with proton beam therapy experience local tumor relapse
- If blind painful eye develops—enucleation

Observation

- If differentiation between nevus and melanoma cannot be made with reasonable certainty
- Also if pt has other life-threatening medical conditions precluding surgical intervention
- If diagnosis of melanoma, observation without intervention may increase risk of death from metastatic disease

Laser Therapy

- Transpupillary thermotherapy (TTT): infrared laser beam directed at tumor via slit lamp or indirect ophthalmoscope—large spot diameter (1-3mm), 60-90 second exposures to completely whiten the lesion
- Pre-exposure intravenous ICG may improve absorption of laser energy in hypomelanotic and amelanotic tumors
- Laser photocoagulation: argon laser, spot size usually 0.5mm, exposure times of 0.5-1 sec or slow movement across tumor with continuous exposure setting
- Also create confluent chorioretinal burn 0.5-1mm wide completely around the base of the tumor

Laser Therapy

- TTT usually used for melanomas up to 3.5mm in thickness
- Photocoagulation usually used for up to 2mm in thickness
- Both methods usually reserved for tumors up to 10mm in diameter with limited or no retinal detachment posterior to equator with clear media
- Desired endpoint: completely flat, atrophic area corresponding to site of prior tumor

Laser Therapy

- Follow-up studies demonstrate relatively high rates of local treatment failure and tumor relapse
- Survival outcome generally substantially better than in patients with radiation therapy or enucleation (due to better prognostic factors to warrant laser instead of more invasive methods)

Cryotherapy

- Unlike with regard to retinoblastoma, cryotherapy has not gained wide acceptance for choroidal or ciliary body melanomas
- Several case reports indicate that cryotherapy is effective in selected cases

Microsurgical Resection

- Trans-scleral resection technique: partial-thickness scleral flap, tumor is resected with microscissors, opening closed with multiple interrupted sutures
- If possible, sensory retina left intact
- Performed under hypotensive general anesthesia to prevent major intraoperative intraocular bleeding
- Endoresection method (less common): PPV, followed by resection of tumor and overlying retina (transretinal technique) or without retina (subretinal technique—retinotomy with reflection of retina away from the lesion)
- High complication rate with both methods, high rate of recurrence
- Plaques immediately after external resection or proton beam therapy before endoresection performed
- Similar prognosis compared to primary enucleation

Exenteration

- Performed for tumors with massive extrascleral extension or for orbital recurrence after enucleation
- Does not usually improve survival compared to more conservative methods
- Radiation commonly performed along with debulking of tumor

Chemotherapy

- Generally not used for tumors confined to the eye (inconsistent results)
- Unfortunately no regimen has been able to eradicate metastatic melanoma

Multimodal Therapy

- Most commonly employed combinations:
 - plaque radiation therapy followed by laser
 - trans-scleral local resection followed immediately by plaque radiotherapy
 - proton beam radiation therapy followed by transvitreal endoresection (within 1-3 days)

Clinical Course

- Clinical prognostic factors for death from metastatic disease without evidence of metastasis:
 - size of tumor (up to 10mm maximal linear dimension called small, 10-15mm medium, and > 15mm large)
 - location (ciliary body tumors worse prognosis than choroidal tumors)
 - age of patient
 - extrascleral tumor extension
- Routine further testing (liver enzymes, CXR, imaging of liver) controversial given no effective therapy for metastatic disease

Back to Our Patient

- Findings, differential diagnosis, and plan discussed at length with patient
- Patient was referred urgently to Dr. Paul Finger for evaluation
- With diagnosis of small choroidal melanoma, various options discussed with patient
- Patient elected to observe and to return within 8 weeks after PET/CT

Reflective Practice

- Pt was treated in a timely manner with appropriate initial management
- It is important to keep an open mind to the differential diagnosis and to consider potential serious sequelae
- In discussion with the patient it is crucial to balance the explanation of the importance of follow up without creating excessive anxiety regarding the presumed diagnosis and its implications

Core Competencies

- Patient Care—compassionate, appropriate, and effective in the evaluation and treatment of this patient.
- Medical Knowledge—comprehensive literature search was performed to better understand the evaluation and treatment of this condition. A better understanding of both basic and clinical science of this condition was attained, and relevant topics were discussed among residents and attending physicians
- Practice-based learning and improvement—Care of patient was discussed among residents and faculty. Scientific studies were reviewed to ensure the highest level of evidence-based practice. Suggested protocols in the literature were analyzed and discussed to refine treatment plan for our patient and future patients
- Interpersonal and communication skills—all questions of the patient and family were answered in a complete and caring manner to allay the fears of the patient and family. A professional relationship based on compassion and trust was established for the patient's wellbeing. Pt was followed adequately for consistently excellent medical care and to maintain this relationship.
- Professionalism—Responsibility of potential complications of medical and surgical treatment regimen was accepted by the entire team and communicated to the patient and family. Professional relationships were established and maintained with physicians from other fields.
- Systems-based Practice—communication with physicians from other fields was emphasized in this case to provide multi-specialty care in the best fashion possible. Acute care was provided, follow up appointments were scheduled, contact information was exchanged, and reports to primary care physician given to ensure a successful long-term outcome.

Thank You

- Dr. Fletcher
- Dr. Calderon
- Dr. Paul Finger