

# Grand Rounds Department of Ophthalmology

SHERRY NARANG M.D.  
SUNY DOWNSTATE MEDICAL CENTER  
February 2, 2012

# Case Presentation

HPI: 7 day-old, ex 28 week male, who was noted to have a large rash on the side of his face on day 3 of life. This is no history of trauma, no eye discharge, and no conjunctival injection.

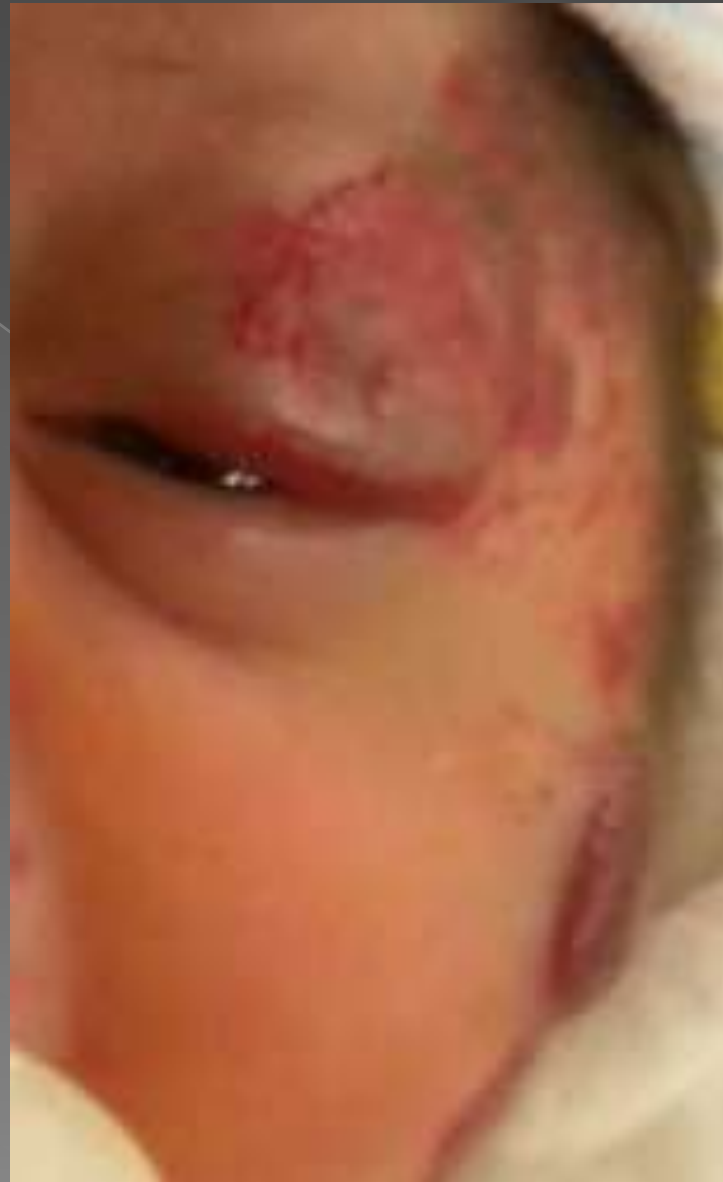# Case Presentation (cont)

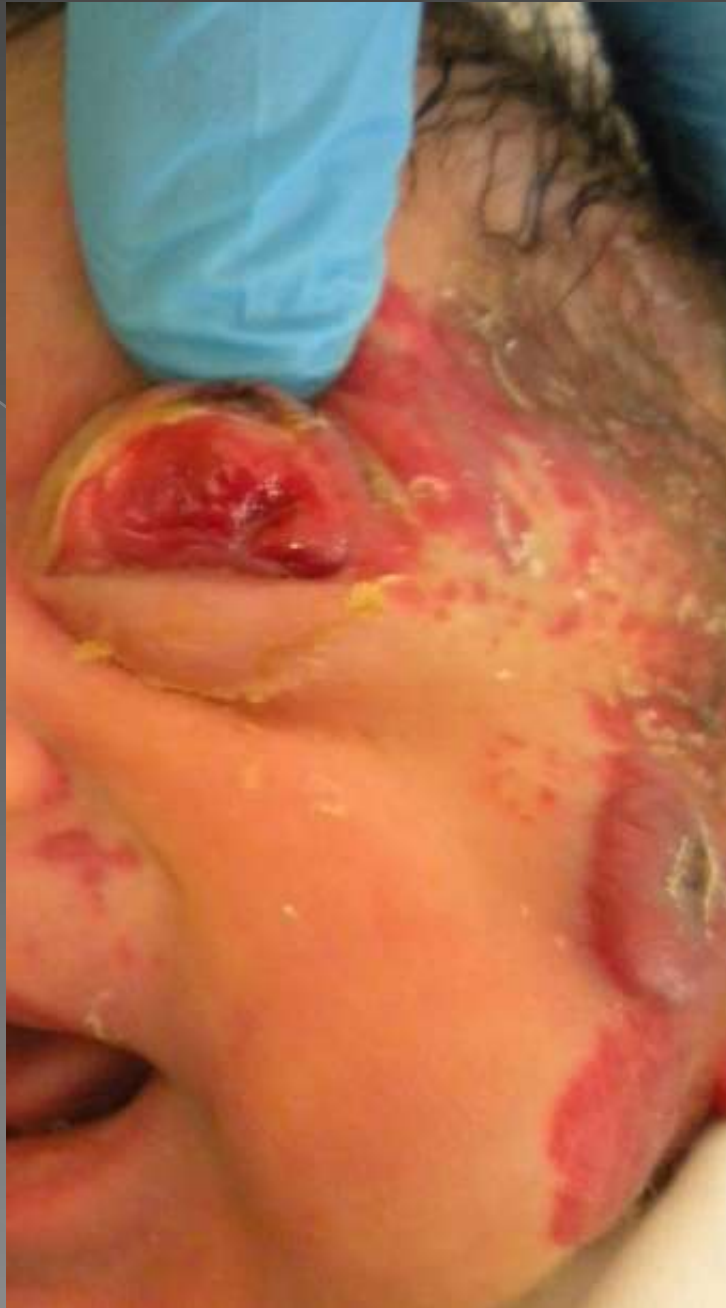- Pregnancy History: GBS+ and Chlamydia+ (treated appropriately)
- Birth History: born at 28 weeks, NSVD, admitted to NICU for respiratory distress syndrome
- Medications: ampicillin and gentamicin
- Eye gtt: none
- NKDA
- Family history: no congenital cataracts or glaucoma

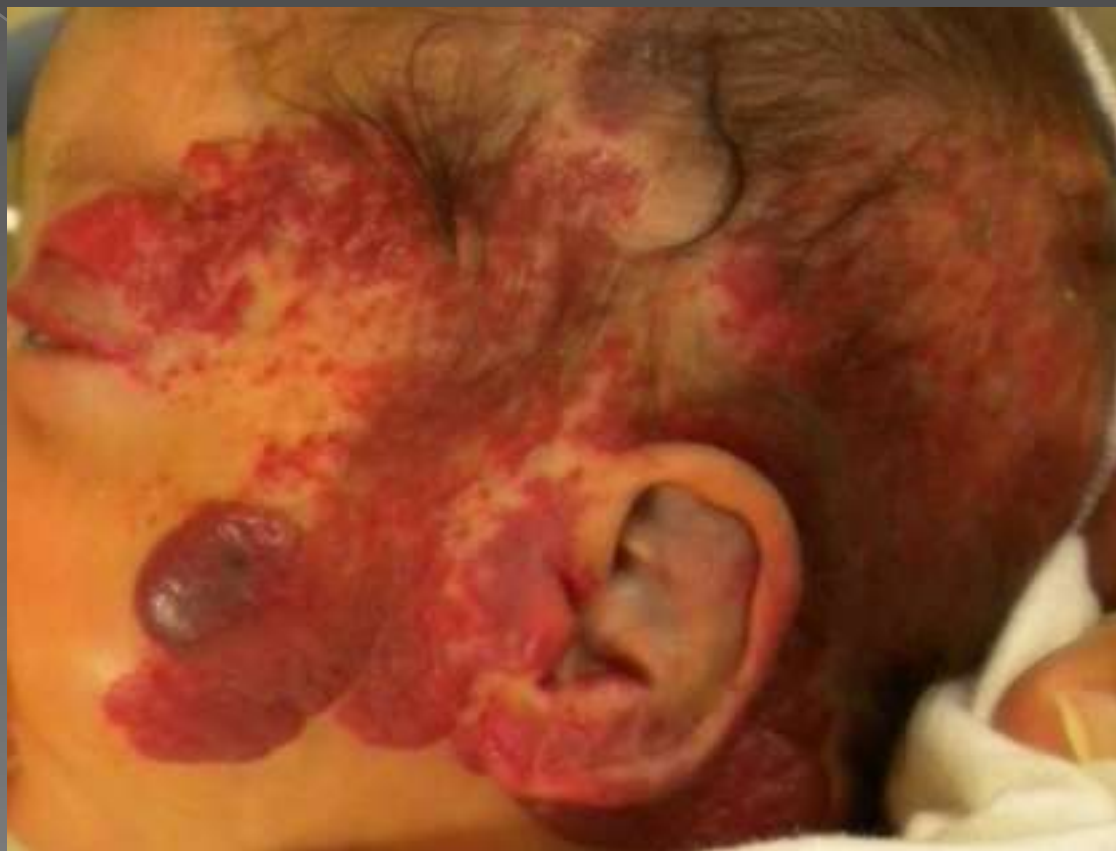# Case Presentation (cont)

## ◉ Exam

- > VA: reacts to light OU
- > EOM: full OU
- > Pupils: pharm dilated OU
- > Tpalp: soft OU







# Case Presentation (cont)

## ● PLE:

- > HEENT/LLA: WNL OD; large dark red, well demarcated, blanching lesion on left upper eyelid continuous to left ear, left neck, and left scalp
- > C/S: white and quiet OD; elevated reddish purple lesion involving palpebral conjunctiva of the left upper lid
- > K: clear OU
- > A/C: formed/symmetric OU
- > I/P: dilated OU
- > L: clear OU



# Case Presentation (con't)

## ○ DFE

- > V: clear OU
- > C/D: sharp/pink OU
- > M: flat OU
- > BV/P: WNL OD; superior choroidal hemangioma OS

# Diagnosis?

- Capillary Hemangioma

# Infantile Hemangioma

- Most common benign orbital tumor in children
- Prevalence: 1-3% in the United States
- Strawberry nevus: irregularly dimpled, elevated surface
- Risk factors: fair skin, females, family history, prematurity, low birth weight, infants born to mothers with placental anomalies, and products of multiple gestations

# Infantile Hemangioma

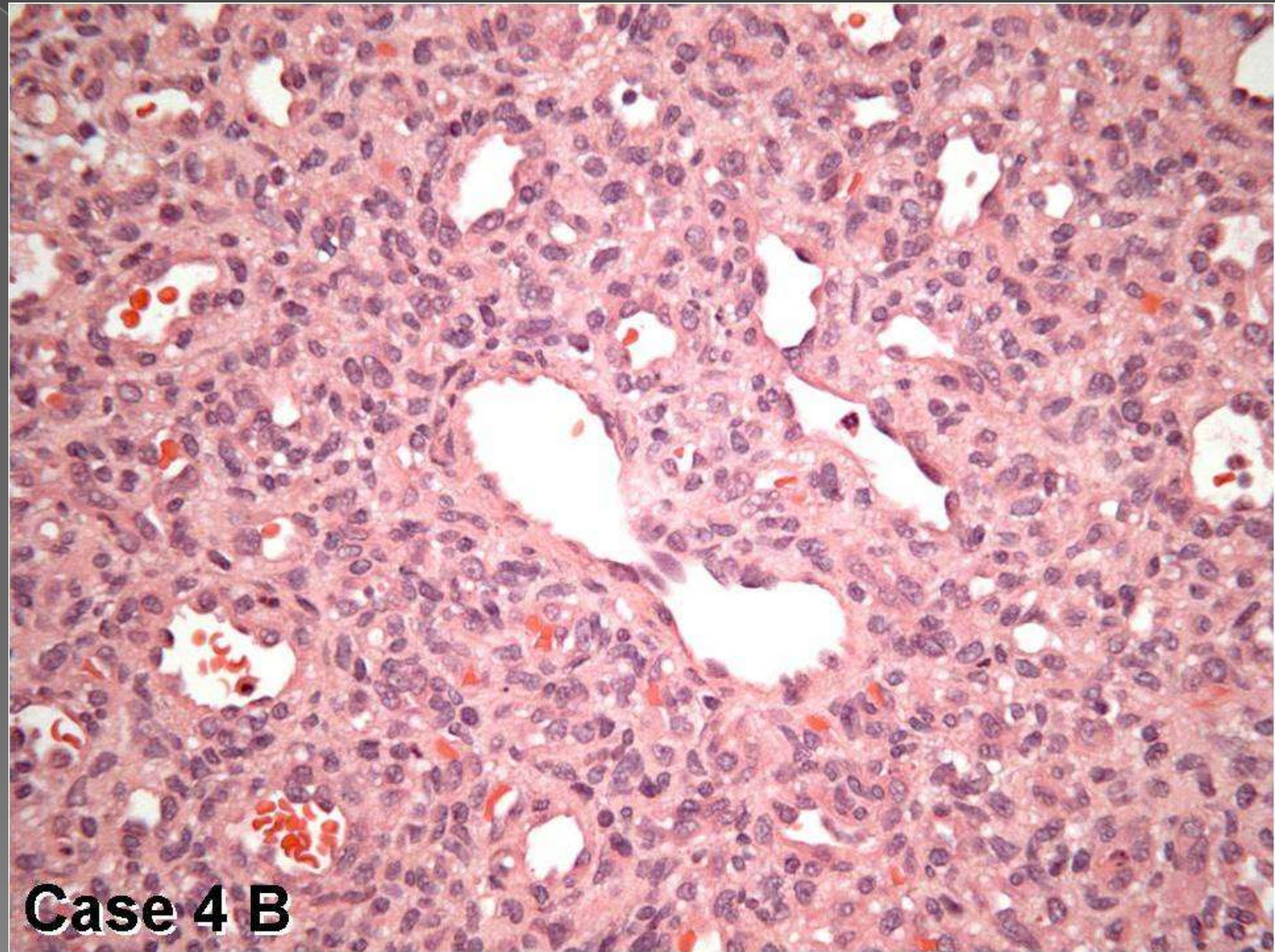
## ○ Phases

### > Proliferation Phase

- Occurs during the first year of life
- Lesion usually not present at birth but develop within the first 3 months of life
- Lesion grows during this phase
- Growth slows or stops towards the end of this phase

### > Involutional Phase

- Occurs over a period of 5-7 years
- 50% involute by age 5, 70% involute by age 7
- It takes an additional 3-5 years to complete process of involution
- May have permanent, residual cutaneous effects (scars, telangiectasia, redundant skin, etc.)



**Case 4 B**

# Infantile Hemangioma

- Ophthalmic complications/indications for treatment
  - > Refractive amblyopia (anisometropic astigmatism)
  - > Deprivation amblyopia (pupillary occlusion)
  - > Strabismic amblyopia (Strabismus from globe compression)
  - > Compressive optic neuropathy
  - > Cosmetic disfigurement

# Infantile Hemangioma

## ● Treatment

### > Systemic Propranolol

- First described in 2008
- Mechanism of Action
  1. Early Phase: Vasoconstriction
  2. Intermediate Phase: Blocks intracellular signaling pathways
  3. Long-term: Inhibit angiogenesis and/or triggers apoptosis of capillary endothelial cells
- Has been shown to shrink lesions and improve astigmatism
- Dosage: 2 mg/kg/day
- Length of treatment guided by clinical improvement
- Toxicities: bradycardia, hypotension, hypoglycemia

# Infantile Hemangioma

## ● Treatment

### > Topical Timolol

- Dosage: 2 drops BID or timolol gel BID
- Small study of 7 children reported 55-95% reduction in hemangioma size and volume and decrease in astigmatism
- Effectiveness depends on the size, depth and thickness of the lesion
- Best for localized, superficial lesions
- Toxicities: similar to systemic propranolol



# Infantile Hemangioma

## ○ Treatment

### > Corticosteroids

- Disrupts vasculogenesis via inhibition of vascular endothelial growth factor
- Stops further growth but causes lesion to shrink in ~ 1/3 of patients
- Systemic or Intralesional
- Toxicities
  - Systemic: hypertension, poor growth, adrenal dysfunction, elevated IOP, immunosuppression, etc
  - Local: hypopigmentation, fat atrophy, eyelid necrosis, central retinal artery occlusion

# Infantile Hemangioma

- Pulse-Dye Laser
  - > Usually second line treatment
  - > Best results during early proliferative and late regression phases when lesion is the flattest
  - > Toxicities: skin atrophy and pigmentary changes
- Surgical Excision
  - > Done for well circumscribed lesions that have failed medical therapy, exhibit fast growth, or cause significant orbital deformity
  - > Can also be done for cosmetic improvement to remove residual fibrofatty tissue
  - > Side effects: scarring, wound complications, hemorrhage
- Chemotherapeutic Agents
  - > Reserved for life or sight threatening lesions
  - > Toxicities: myelosuppression, hepatotoxicity, neurotoxicity
  - > May be combined with other treatment modalities or used in low doses to decrease side effects

# Infantile Hemangioma

## ◉ Complications

### > Kasabach-Merritt syndrome

- Occurs with large hemangiomas
- Consumptive coagulopathy and platelet trapping
- Can have disseminated intravascular coagulation and/or high-output congestive heart failure

## ◎ PHACES

- > **P**osterior fossa malformations, **h**emangiomas, **a**rterial anomalies, **c**ardiac defects, **e**ye abnormalities, and **s**ternal clefting

## ◎ Sturge-Weber (aka encephalotrigeminal angiomatosis)

- > Port-wine stain in V1 and V2 distributions, glaucoma, seizures, leptomeningeal angioma, mental retardation
  - PWS: flat lesion, may initially be light pink and progressively darkens over time, does not blanch with pressure

# Our Patient

- Our patient was diagnosed with PHACES syndrome. He was noted to initially have a small amount of astigmatism in the left eye. He was started on timolol gel and propranolol. After some adjustments to the medication regimen, he was noted to have some decrease in the size of the hemangioma and his astigmatism improved. He is still currently on propranolol (~ 2mg/kg/day) and timolol gel 3x/day.

# Reflective Practice

- This was an interesting, yet challenging case
- It involved coordinating care and good communication between our team, dermatology, the NICU team, and the patient's parents
- He received appropriate and timely medical care

# Core Competencies

- Patient Care-our patient received the appropriate medical treatment and referral for his condition as per evidence based medicine.
- Medical Knowledge-we used this case as a learning opportunity to increase our knowledge about capillary hemangiomas
- Practice Based Learning and Improvement-this case helped us to focus our learning on the current treatment modalities for capillary hemangiomas

# Core Competencies

- Interpersonal and Communication Skills-We were able to communicate with the other involved specialties and the patient's family regarding his condition.
- Professionalism-we discussed the treatment options with the patient's family in a manner that they understood all of the risks, benefits, and alternatives.
- Systems Based Practice-we demonstrated an awareness of the health care system so that we could effectively call upon our resources and provide the best treatment for our patient.



# References

- Haggstrom, A.N, et al. "Prospective study of infantile hemangiomas: demographic, prenatal, and perinatal characteristics." *J Pediatr*. 2007 Mar;150(3):291-4.
- Ni N, Guo S, Langer P. "Current concepts in the management of periocular infantile (capillary) hemangioma." *Curr Opin Ophthalmol*. 2011 Sep;22(5):419-25.
- Claerhout I, et al. "The use of propranolol in the treatment of periocular infantile haemangiomas: a review." *Br J Ophthalmol*. 2011 Sep;95(9):1199-202.

# Thank You

- ◉ Dr. Kumar
- ◉ Dr. Shinder
- ◉ Dr. Gorski
- ◉ Dr. Shah