

Ophthalmology Grand Rounds

SUNY Downstate Medical Center
Asher Neren MD
July 18, 2013

HPI

- 63 yo Female presents for initial exam. States she had noticed a decrease in her vision OU starting in her mid-50's. Otherwise, no ocular complaints.
- Denies any flashes or floaters OU
- Patient History:
- PMH: (+) HTN (+) DM (last A1C 6.2), (+) HLD, Benign Thyroid Nodule
- POH: Denies
- Gtts: None
- Meds: Metformin, ASA 81, Glipizide, Januvia, Metoprolol, Lisinopril
- FH: (-) glaucoma
- Allergies: PCN
- Social History: neg x 3

Exam

VA cc:

- OD: 20/50
- OS: 20/60

- Mrx:
- OD: +2.25 -1.25 x 95 20/40
- OS: +2.25 -1.00 x 105 20/40

Pupils: 3→2 , no apd ou

EOM: full

CVF: full

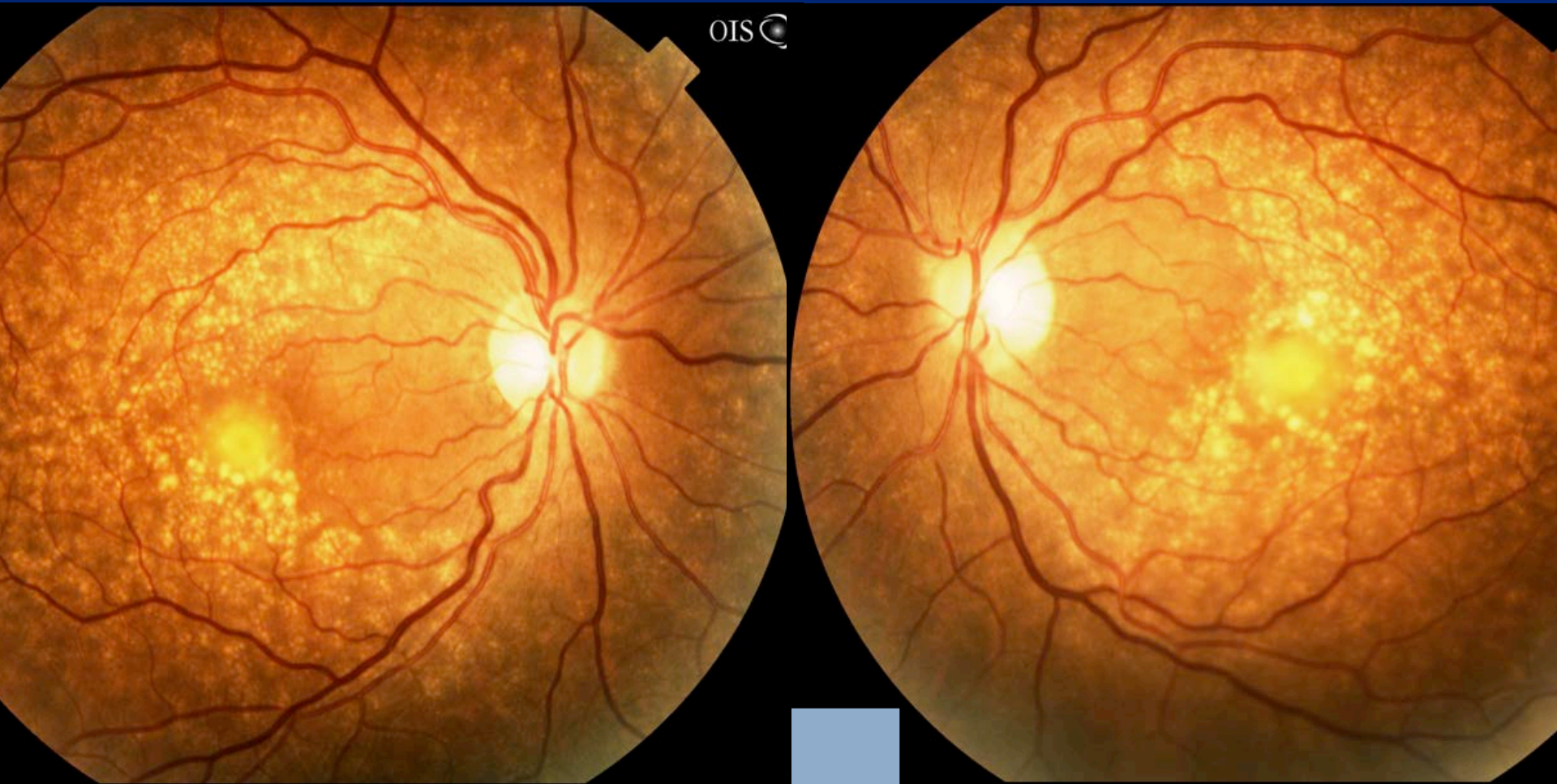Tapp: 20/20

Slit Lamp Exam

- **L/L/A: wnl ou**
- **C/S: w and q ou**
- **K: clear ou**
- **A/C: deep and quiet ou**
- **I/P: round and reactive ou, + nevus 5 o' clock OS,
(-) nvi ou**
- **L: trace NS OU**

- **DFE: See Photos**

Fundus Photos



Next Step ?

OCT macula

Thickness Map Single Exam Report OU SPECTRALIS® Tracking Laser Tomography



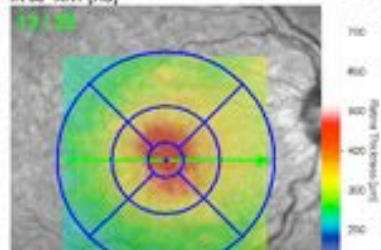
Patient: [REDACTED]
Patient ID: [REDACTED]
Diagnosis: ---

DOB: [REDACTED]
Exam.: [REDACTED]
Comment: ---

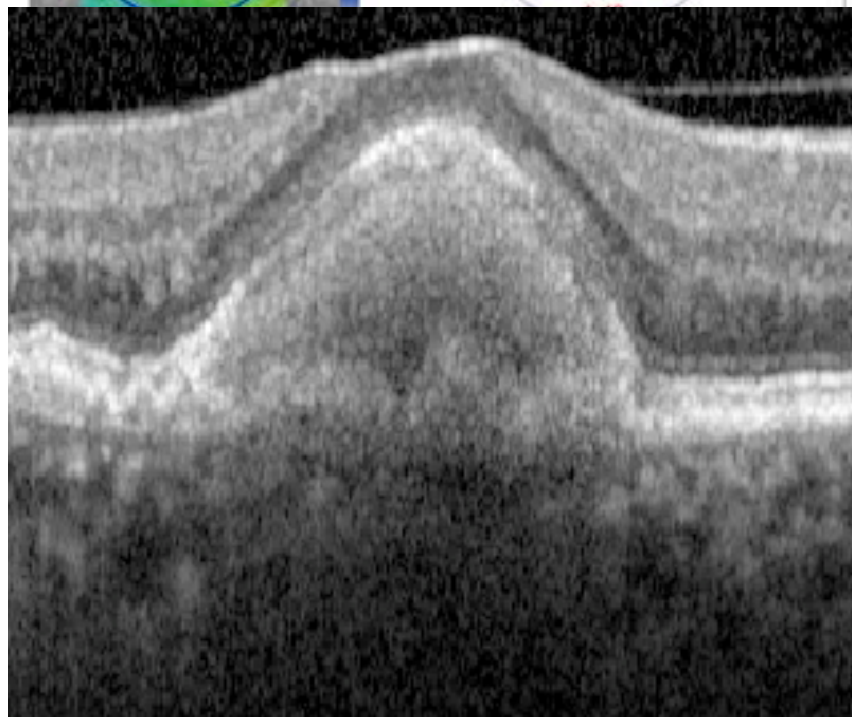
Sex: F

OD

IR 30° ART (HS)

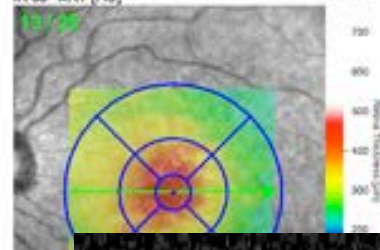


Average Thickness [μm]

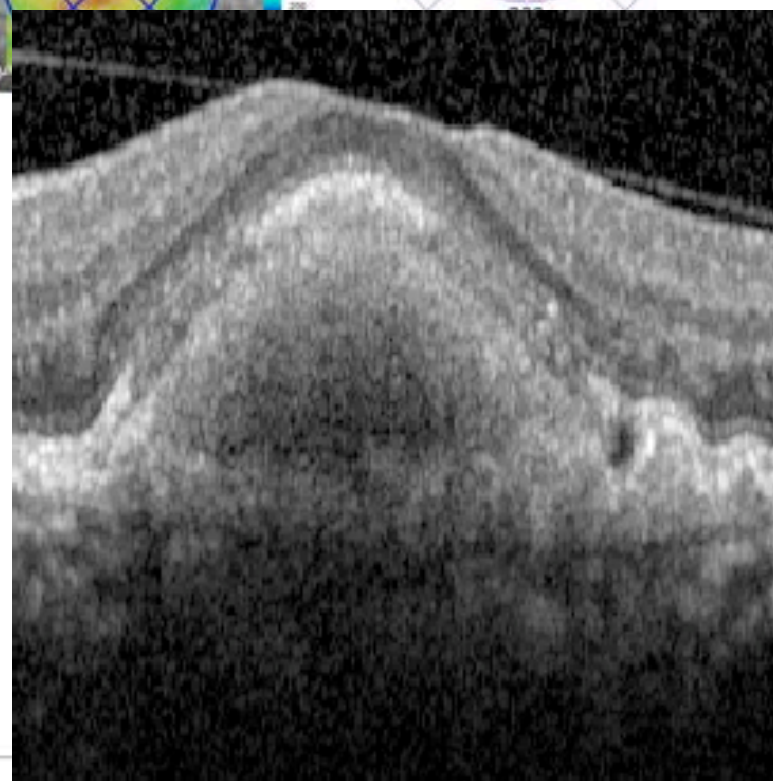


OS

IR 30° ART (HS)

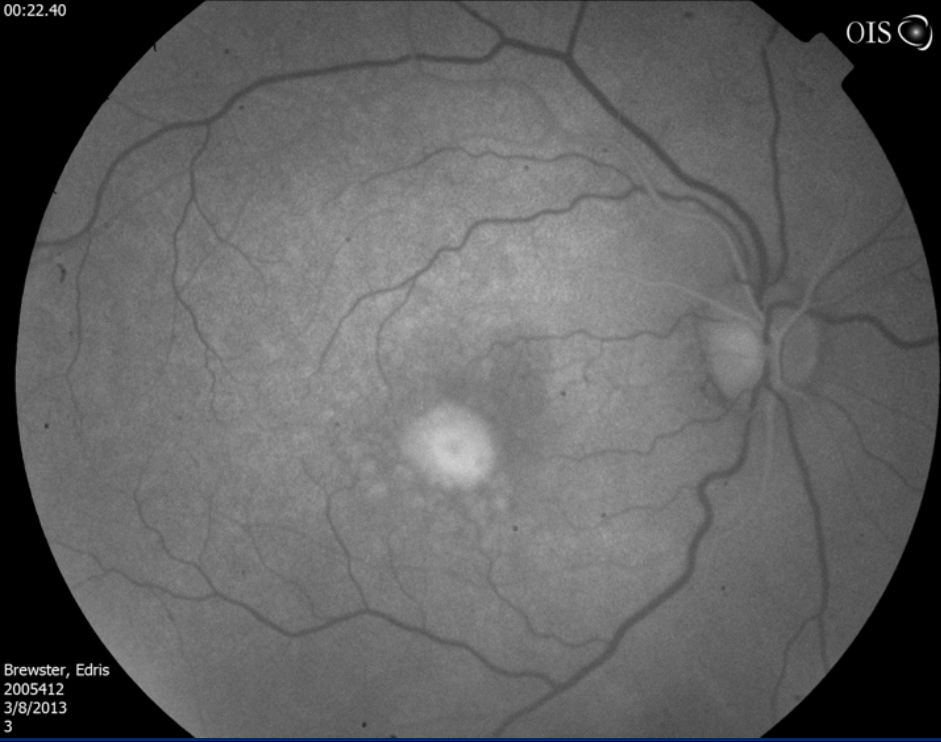

Average Thickness [μm]

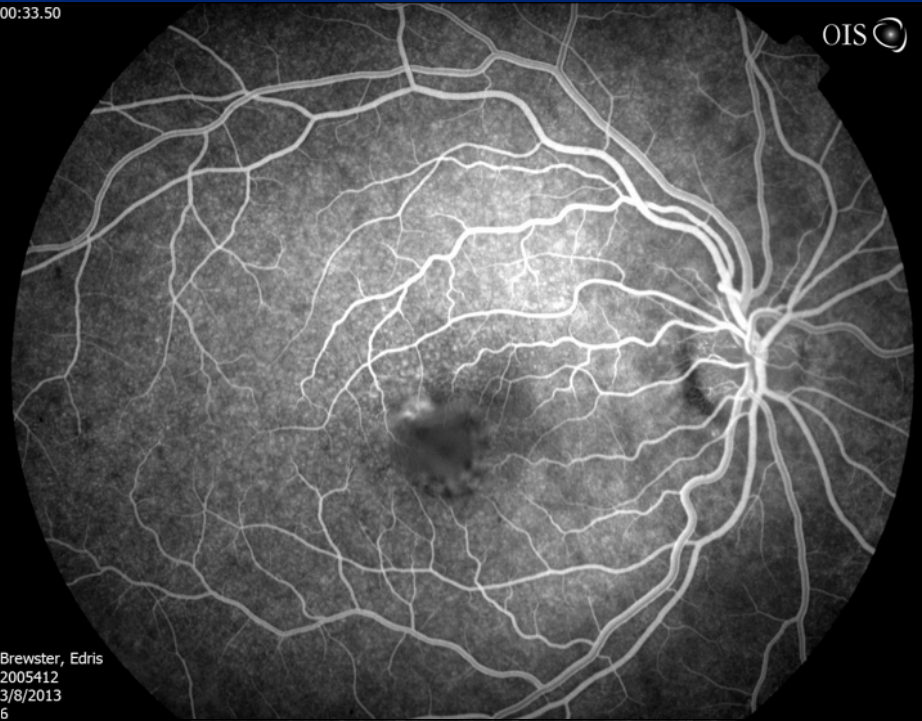


[REDACTED]

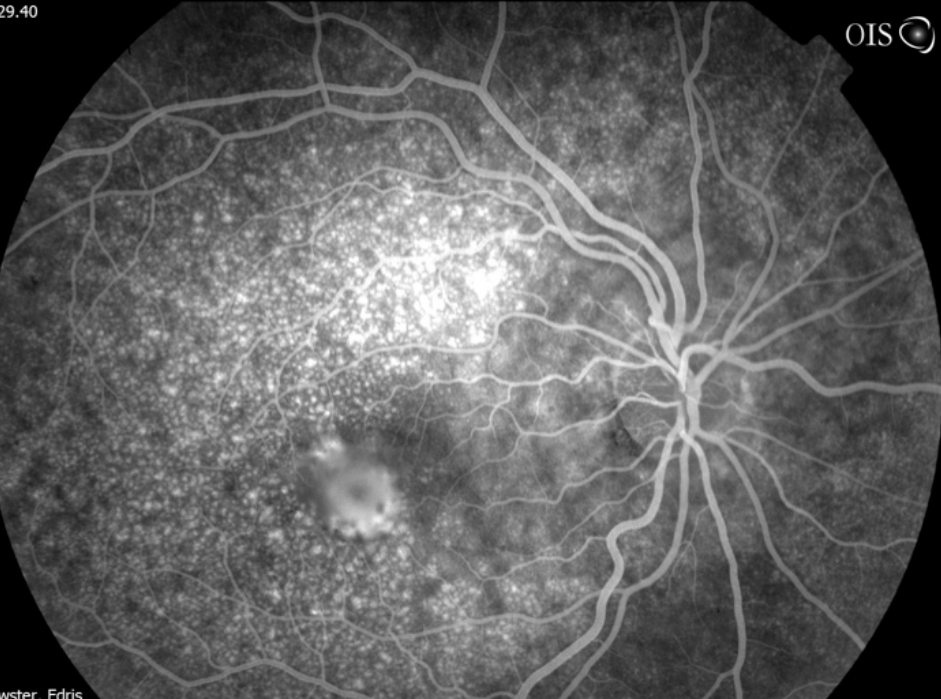
Signature:



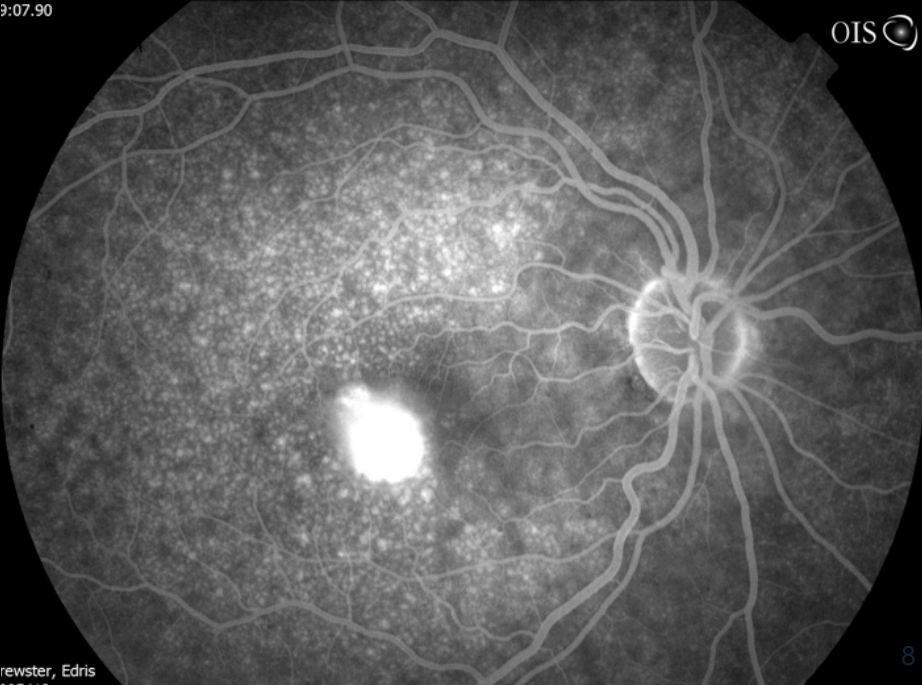
Brewster, Edris
 2005412
 3/8/2013
 3



Brewster, Edris
 2005412
 3/8/2013
 6



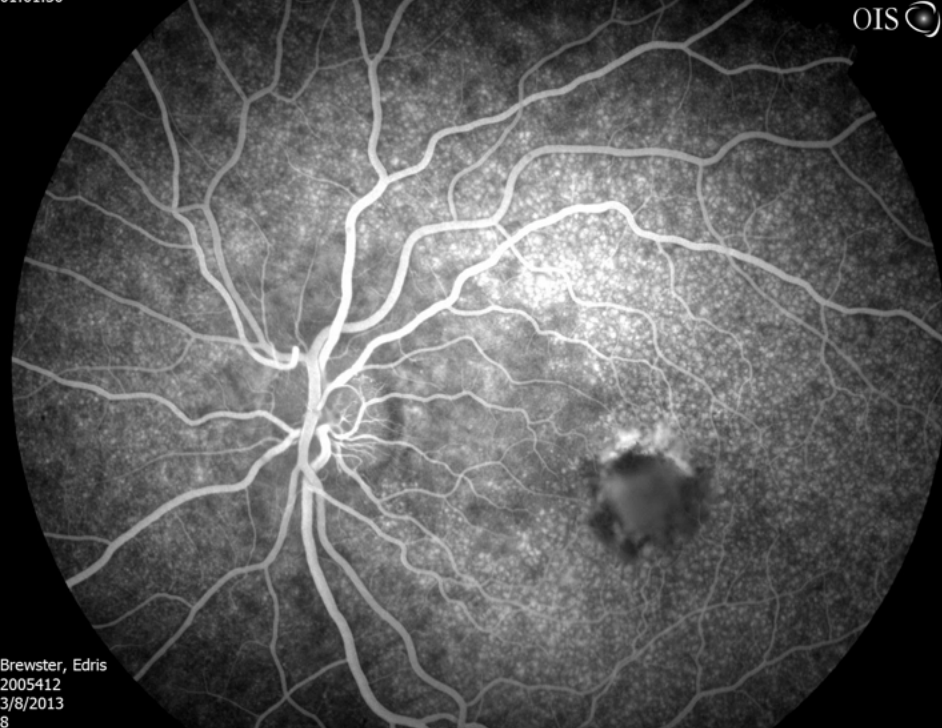
ewster, Edris



rewster, Edris

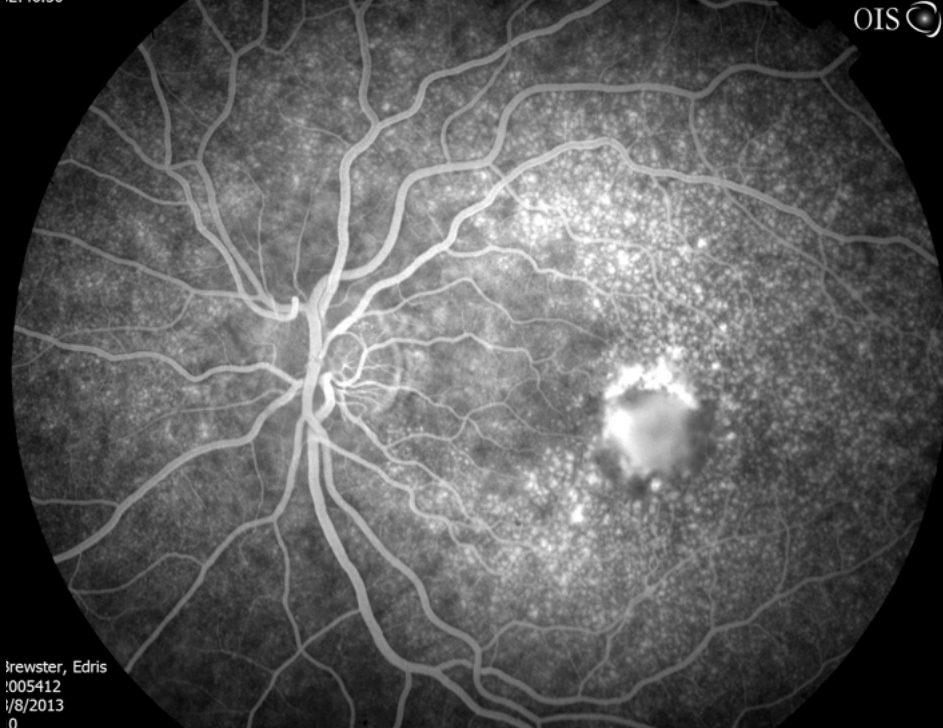
01:01.30

OIS



12:46.50

OIS

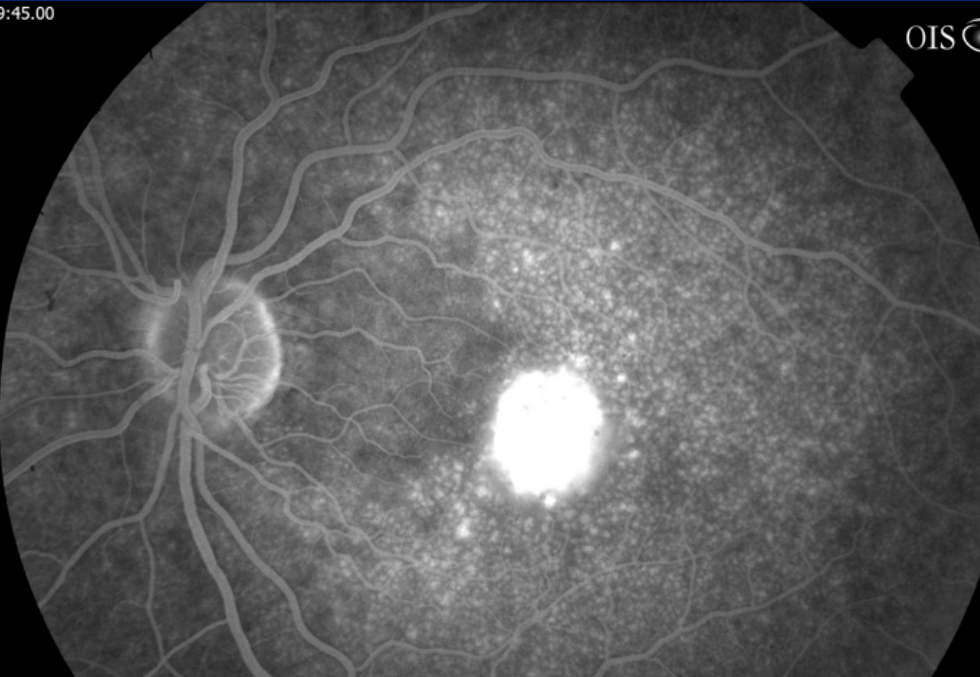


Brewster, Edris
2005412
3/8/2013
8

Brewster, Edris
2005412
3/8/2013
0

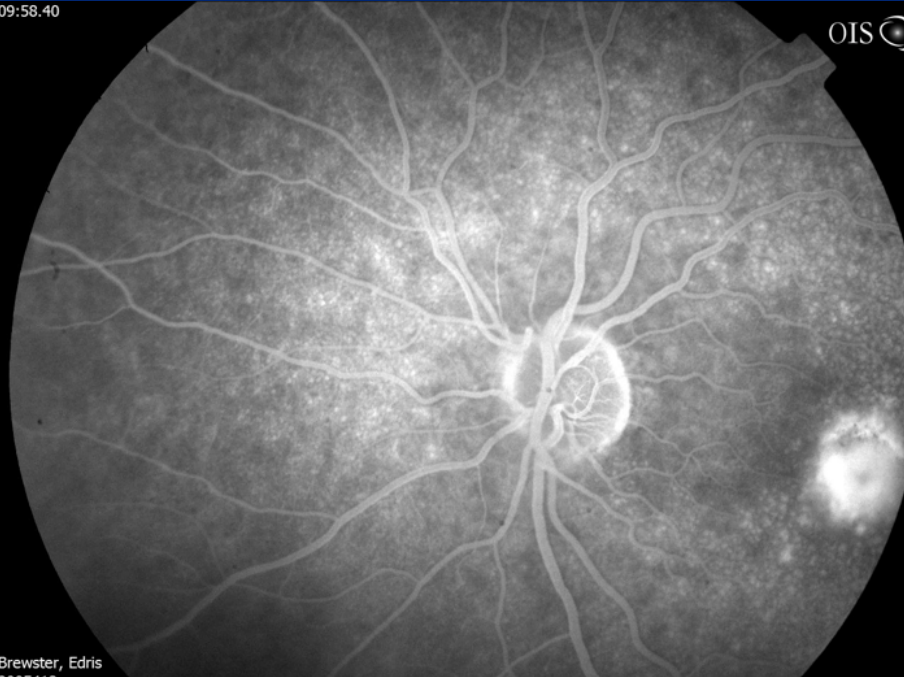
09:45.00

OIS



09:58.40

OIS



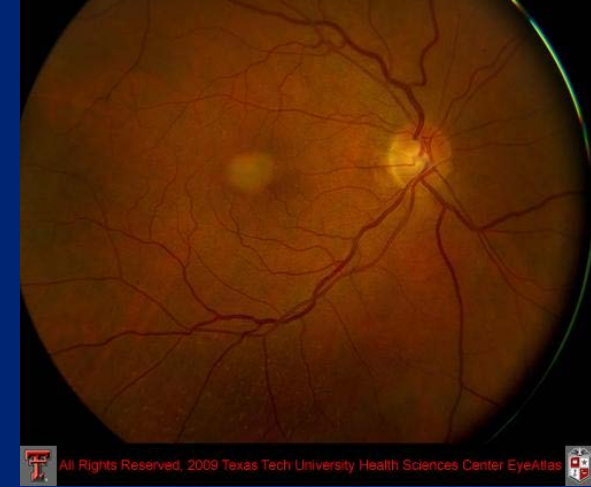Brewster, Edris
2005412

Differential Diagnosis

Differential Diagnosis

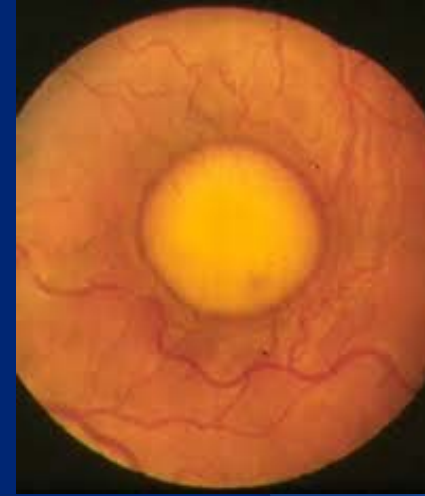- ⦿ **Acquired Vitelliform Macular Dystrophy**
- ⦿ **Best's Disease**
- ⦿ **Age Related Macular Degeneration**
- ⦿ **Dominant Drusen**
- ⦿ **Central Serous Chorioretinopathy**
- ⦿ **Pigment Epithelial Detachment**
- ⦿ **Stargardt's Disease**
- ⦿ **Sorsby's Fundus Dystrophy**
- ⦿ **Pattern Dystrophies**

Acquired Vitelliform Macular Dystrophy (AVMD)



- First reported by Gass in 1974
- Characterized by a bilateral, yellow, solitary, round or oval subretinal macular lesion, 1/3- 1 DD in size with a central pigmented spot that resembles juvenile onset vitelliform macular dystrophy, or Best Disease
- Onset between ages 30 and 50 years with asymptomatic or mild decrease of visual acuity
- Mutation found in the RDS or peripherin gene as well as the VMD2 gene
- However, less than a quarter of all people have these mutations
- **Autosomal dominant disorder, but many affected individuals have no history of the disorder in their family**
- Minimally decreased electro-oculogram (EOG)
- Clinicopathological studies show a massive accumulation of lipofuscin pigments within the macular retinal pigment epithelium (RPE), and loss of the RPE and photoreceptor cell layer with infiltration of pigment containing macrophages in the central area

Best Vitelliform Macular Dystrophy (BVMD)



- Also known as vitelliform macular dystrophy Type 2, or Best Disease
- Initially described by Franz Best in 1905
- Autosomal dominant form of macular degeneration of variable penetrance
- Characterized by varying accumulation of yellowish vitelliform material in the macula
- Mutation found in the VMD2, or “bestrophin” gene, located on chromosome 11, which encodes a transmembrane chloride channel localized in the RPE basement membrane
- 48 different mutations discovered that generally affect amino acids in the first 50% of the protein, and occur in four distinct clusters representing regions of functional importance
- Presents in childhood or early adulthood, and usually portends a good visual prognosis
- A decrease in the EOG (measure of electrical potential across RPE) is a pathognomonic characteristic

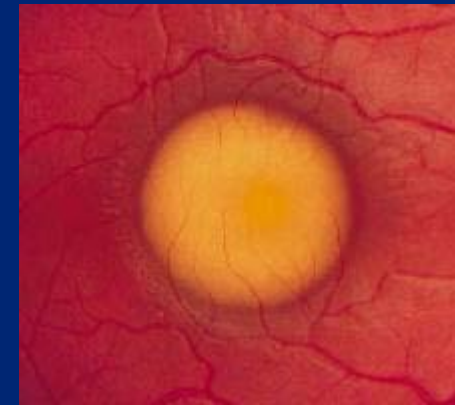Pathophysiology

- The abnormal chloride channel in the RPE leads to changes in the photoreceptor inner segment/outer segments
- Buildup of un-phagocytosed outer segments accumulate because of the lack of apposition of the outer membrane segments to the RPE
- The persistence of the material in the subretinal space causes the formation of lipofuscin precursors, a retinal breakdown pigment, which are susceptible to oxidative damage
- In the advanced disease state, lipofuscin gets reabsorbed or disappears, causing atrophy in the RPE
- Choroidal neovascularization (CNV) may occur and can cause rapid, significant visual loss

Best Disease

- In 1981, Mohler and Fine described a 5 stage clinical classification of BVMD, based on the appearance of the vitelliform lesions and Gass added the sixth stage
- Stage I (Previtelliform): normal vision, normal or only subtle RPE changes with abnormal EOG.
- Stage II (Vitelliform): classic “egg-yolk” lesion. 30% have satellite lesions. Normal vision or mild vision loss.
- Stage III (Pseudohypopyon): layering of lipofuscin. Vision similar to stage II.
- Stage IV (Vitellerruptive): breakup of material gives “scrambled egg” appearance.
- Stage V (Atrophic): Central RPE and retinal atrophy. Vision may range from 20/30 – 20/200.
- Stage VI (CNV): Occurs in about 20% of patients. Vision often decreased to 20/200 or worse.

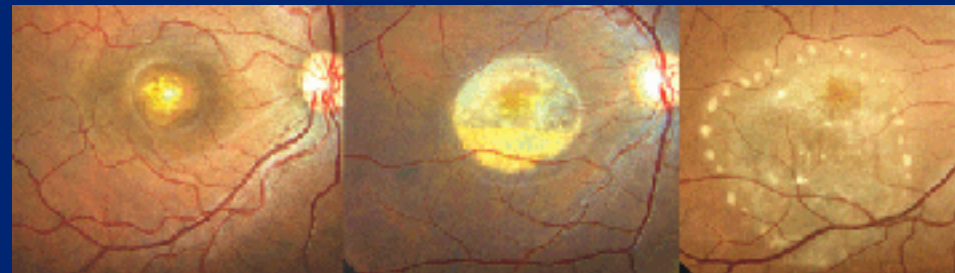
Vitelliform



Atrophic

Pseudohypopyon

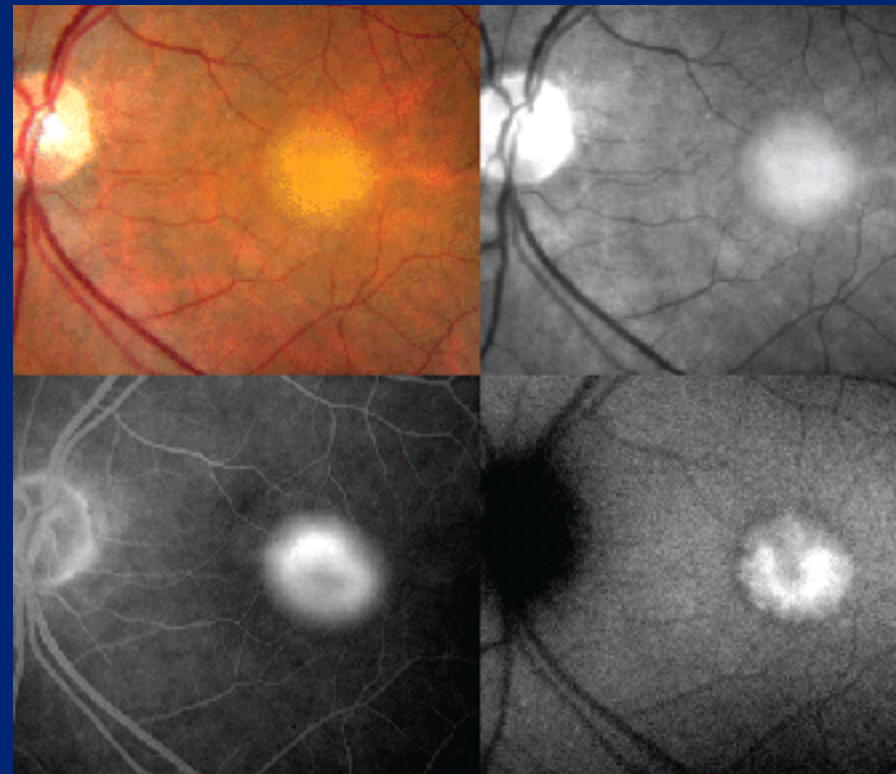
Vitellerruptive



Revophth.com

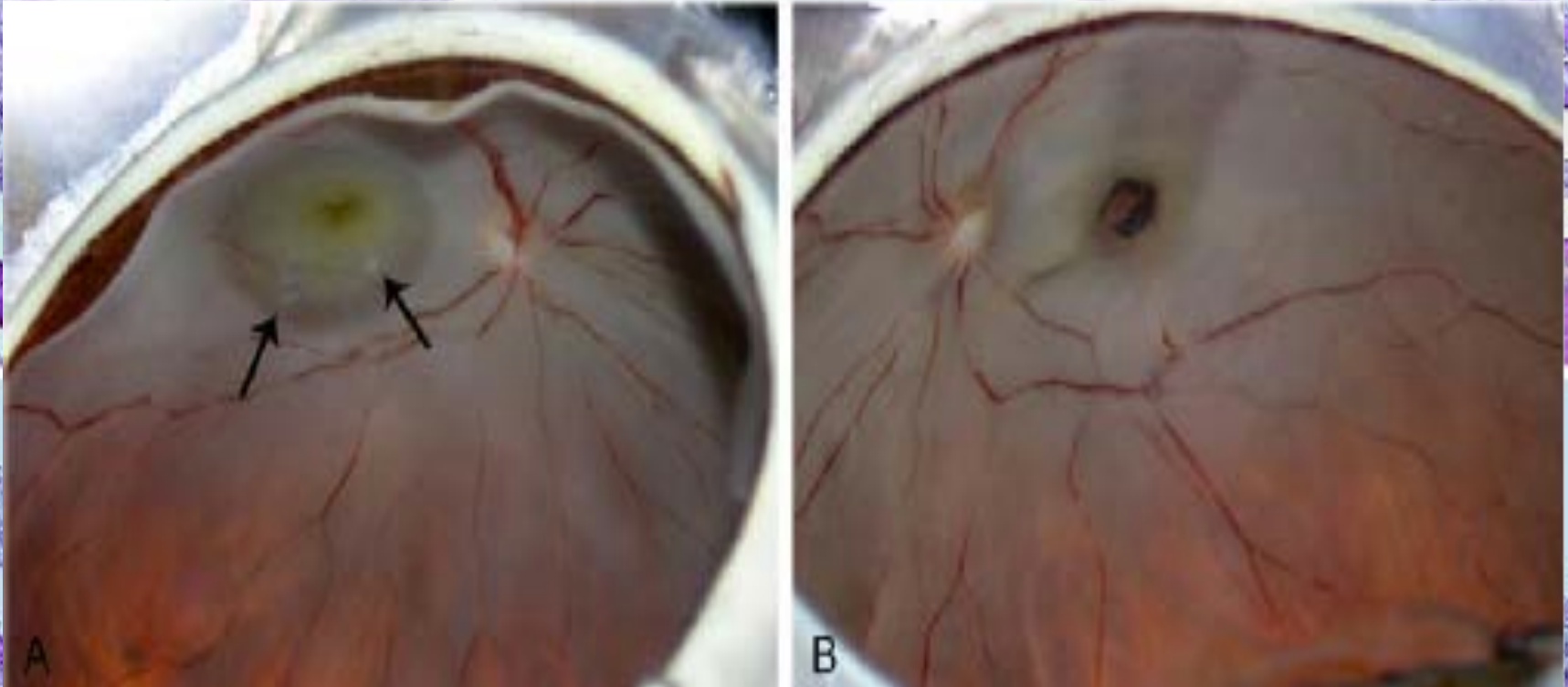
Fluorescein Angiography

- Hypofluorescence of typical vitelliform lesion, and as the disease progresses a mixed pattern of hyper and hypofluorescence eventually gives way to hyperfluorescence during atrophic stage.
- Fundus Autofluorescence (FAF):
- Hyperautofluorescence during the earlier vitelliform stages
- Hyperautofluorescence settles with the pseudohypopyon stage, and becomes mottled with areas of hypofluorescence during the vitelloruptive stage, and eventually becomes hypofluorescent during the atrophic stage.



Revophtho.com

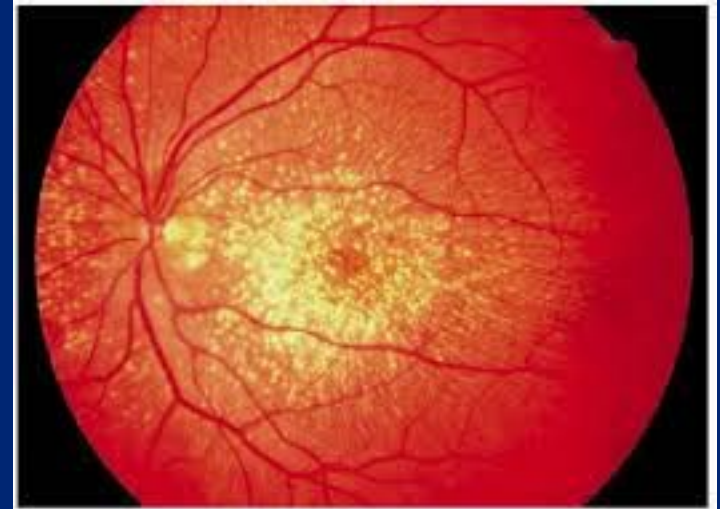Histopathology



Zhang, Q, Small, K, Grossniklaus, H Bilyk JR. Clinicopathologic findings in Best vitelliform macular dystrophy. **Graefes Arch Clin Exp Ophthalmol.** 2011 May ; 249(5): 745–751

Dominant Drusen

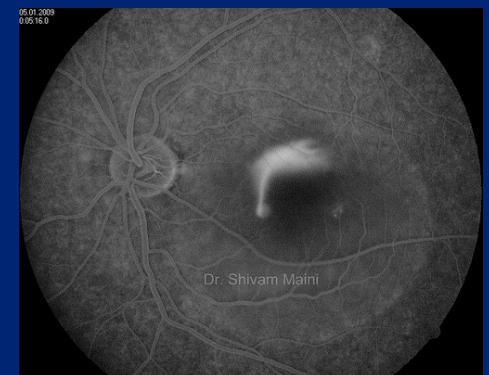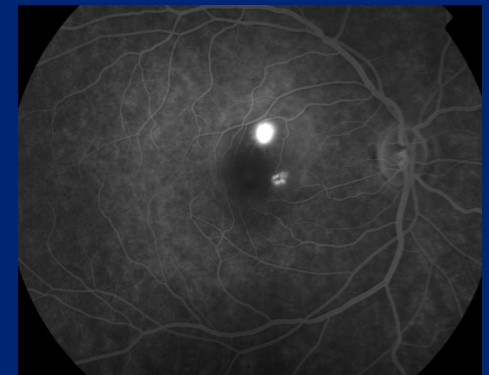
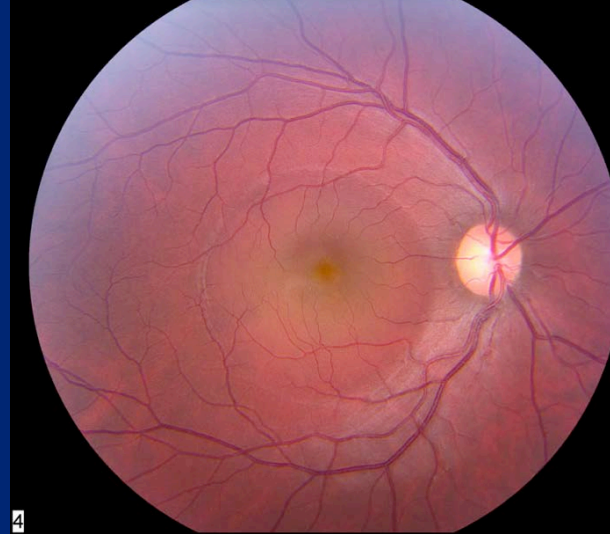- Also known as Doyne honeycomb retinal dystrophy and Malattia Leventinese
- Inherited dominant drusen represent nodular thickening of the RPE basement membrane forming a honeycomb pattern in the area of the optic disc and macula.
- Controversial whether they represent a distinct entity or are just an early manifestation of AMD
- The onset of symptoms is during the third or fourth decade (earlier than AMD)
- Thought to be caused by a single mutation in a gene called FBLN3
- ARMD is caused by mutations in other genes (eg. fibulin5, RPGR, HEMICENTIN-1, and complement factor H), which also lead to drusen deposits



Drugline.org

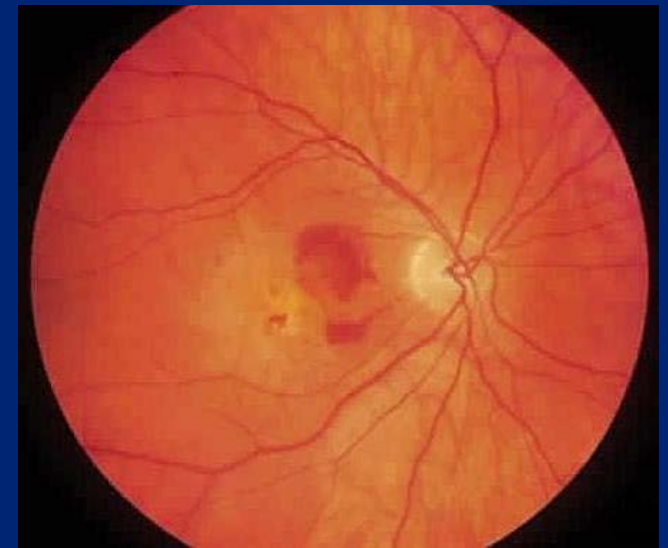
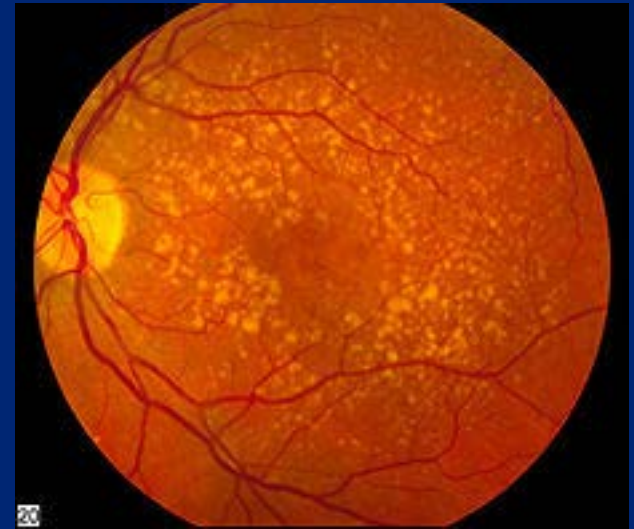Central Serous Chorioretinopathy

- Pinpoint leakage relative to large area of subretinal fluid
- Serous pigment epithelial detachments
- FA findings: expansile dot, smokestack, diffuse
- Choroidal vascular abnormalities
- Filling delays in choroidal arteries and choriocapillaris leading to hyperpermeability of choroidal vessels



Age Related Macular Degeneration

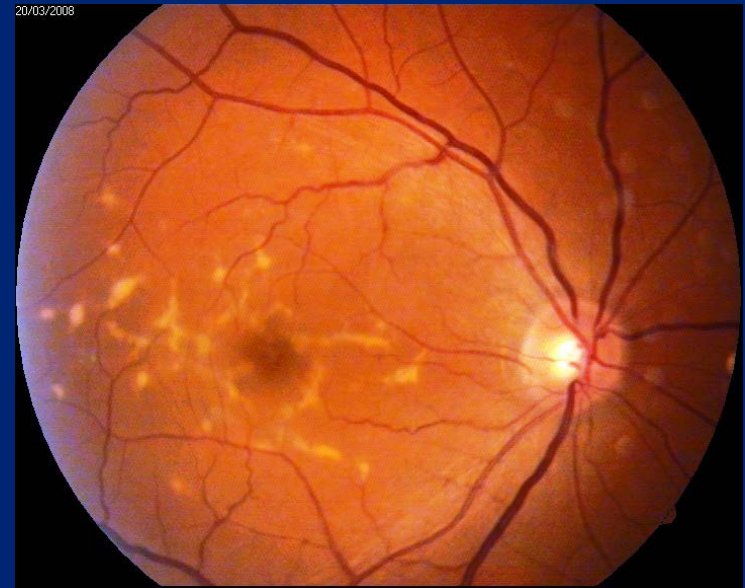- Characterized by yellow drusen in the macula, between the RPE and choroid
- Central geographic atrophy
- the "dry" form of advanced AMD
- Results from atrophy of the retinal pigment epithelial layer, which causes vision loss through loss of photoreceptors
- Neo-vascular or Exudative AMD:
- the "wet" form of advanced AMD, causes vision loss due to CNV
- 10% of patients suffering from macular degeneration have the wet type



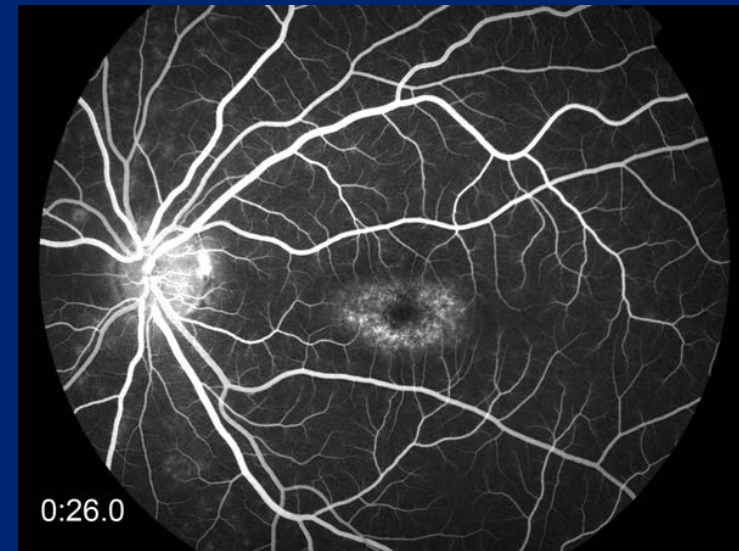
NEI

Stargardt Disease

- Most common form of juvenile macular degeneration
- Classically, presents in childhood with decreased central vision, foveal atrophy, and yellow pisciform flecks at the level of the RPE in the macula
- Autosomal recessive disorder with defect in the ABCA4 gene
- Stargardt patients should avoid a diet high in vitamin A because the defective gene encodes for a transmembrane transporter of A2E intermediates, a toxic by-product of vitamin A
- At least 80% of Stargardt patients have a “silent choroid,” which is a dark choroid on fluorescein angiogram which is attributed to A2E accumulation in the RPE



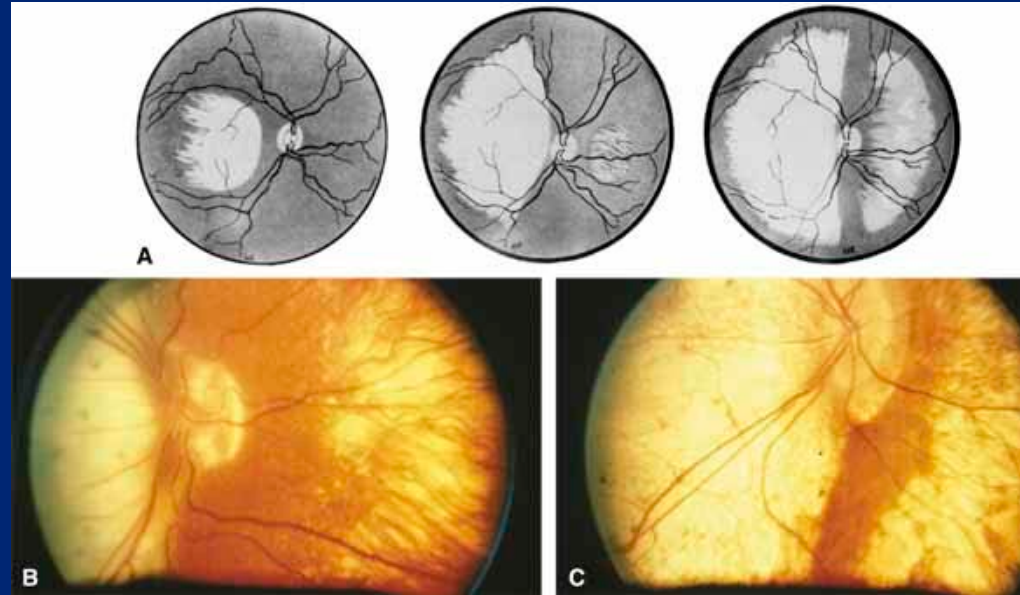
Paliwaleye.com



webvision.med.utah.edu

Sorsby's Fundus Dystrophy

- Characterized by progressive degeneration of the central macula with edema, hemorrhages and exudates with pigment changes
- Autosomal dominant disorder, caused by mutations in the TIMP3 gene, located on chromosome 22, leading to a defect in maintenance and renewal of bruch's membrane
- Onset is typically in the second to fourth decade with development of disciform central macular atrophy
- In late stages progresses to involve the peripheral retina
- Followed by subretinal neovascular membranes in the majority of patients



Oculist.net

Pattern Dystrophies

◎ 5 Types:

- ◎ **Acquired Vitelliform Macular Dystrophy**
- ◎ **Butterfly-Shaped Pattern Dystrophy**
- ◎ **Reticular Dystrophy of the RPE**
- ◎ **Multifocal Pattern Dystrophy Simulating Fundus Flavimaculatus**
- ◎ **Fundus Pulverulentus**

Pattern Dystrophies

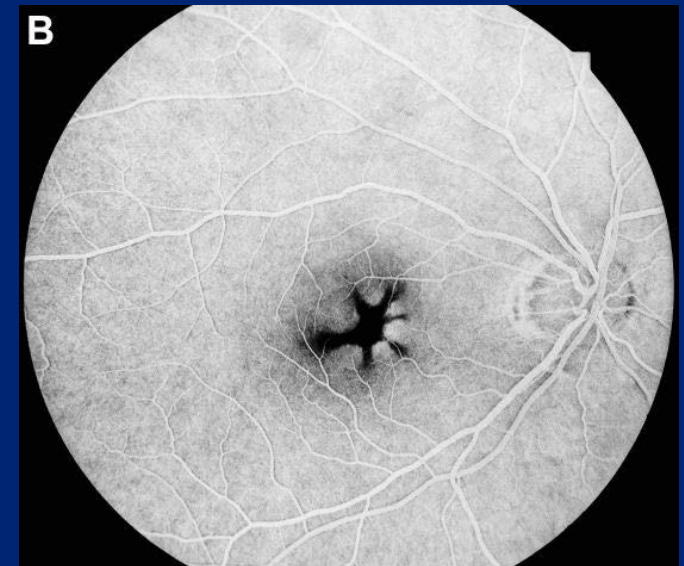
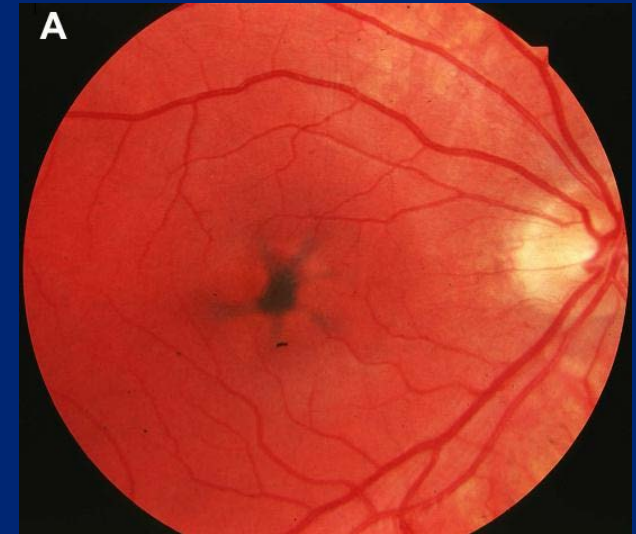
- ⊙ Represent a group of disorders that present in midlife with mild visual disturbances in one or both eyes
- ⊙ Present with various patterns of yellow, orange, or gray pigment deposits in the macular area.
- ⊙ Caused by various mutations in the RDS/peripherin gene on chromosome 6
- ⊙ RDS/peripherin gene encodes a photoreceptor-specific glycoprotein that may play a role in the development and maintenance of photoreceptor outer segment discs

Pattern Dystrophy: Epidemiology

- Since patients present later in life with this condition, they are often misdiagnosed as having ARMD since they share many similar features
- Patients may show different patterns between the two eyes and may show progression from one pattern to another over several years
- Patients can have a pattern dystrophy in just one eye since it may not yet have presented in the fellow eye
- Classically described as having a “benign” course
- However, development of CNV can result in severe vision loss

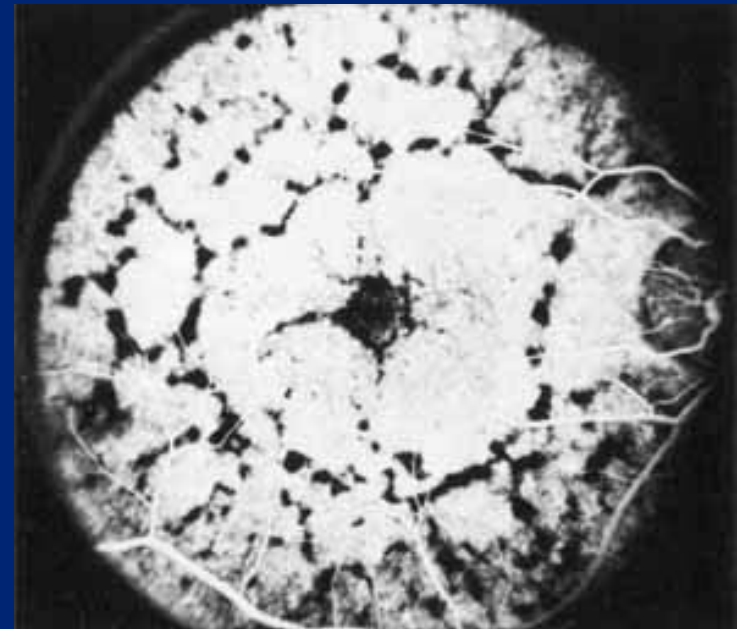
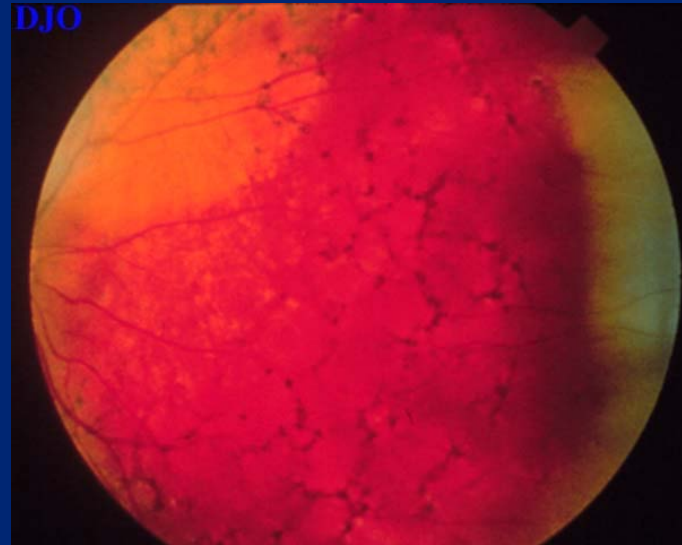
Butterfly-Shaped Pattern Dystrophy (BPD)

- First described by Deutman in a Caucasian family who displayed peculiar bilateral butterfly-shaped pigmentations in the macular region at the level of the RPE
- The central lesion is readily demonstrated by fluorescein angiography, which helps to distinguish this condition from other PDs of the macula
- On fundus autofluorescence, lesions may show increased as well as decreased autofluorescence, corresponding with changes in RPE lipofuscin within the lesion.
- Patients are generally asymptomatic when diagnosed with BPD in their second or third decade and retain relatively normal visual acuity for most of their lives.
- However, the disease can progress with age, and may exhibit atrophic, de-pigmented lesions extending into the peripapillary region, with markedly reduced visual acuity



Reticular Dystrophy of the RPE (RD)

- First described by Sjögren in 1950 as “dystrophia reticularis laminae pigmentosa retinae.”
- Also known as Sjögren reticular dystrophy
- Appearance resembles a reticular network of darkly pigmented lines covering the posterior pole, with pigmented knots present at the intersection of the dark lines, resembling a fishing net with knots
- Lesion usually starts at the fovea and then gradually extends to involve the whole posterior pole
- Usually fades with age but may also be replaced by extensive atrophic changes in the RPE
- FA shows clear hypofluorescent reticular net outlining areas of diffuse hyperfluorescence

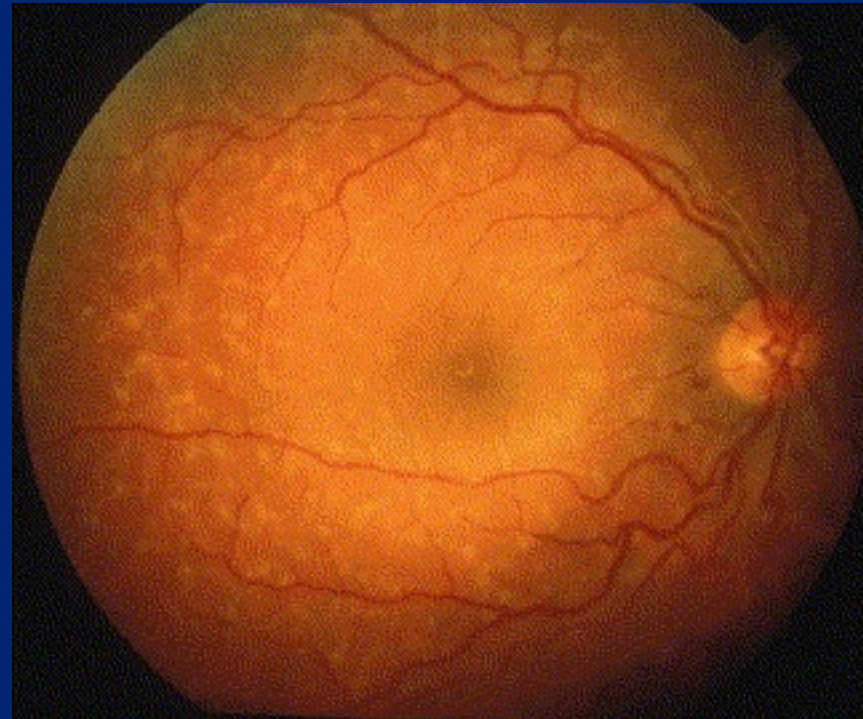


Arch Ophthalmol 96:1177, 1978.

Multifocal Pattern Dystrophy

Stimulating Stargardt's Disease

- Characterized by irregular yellow-white flecks scattered throughout the posterior pole, often extending beyond the retinal vascular arcades
- Macular abnormalities may range from various patterns of yellow or grayish deposits to well-demarcated lesions of severe chorioretinal atrophy
- Flecks seen in multifocal pattern dystrophy resemble those encountered in Stargardt's/ fundus flavimaculatus, an autosomal recessive retinal dystrophy caused by mutation in the ABCA4 gene
- Contrary to Stargardt's, fluorescein angiography in multifocal pattern dystrophy generally does not show a so-called dark choroid.
- A mild to severe constriction of the peripheral visual field is seen
- With advanced disease, cone and rod function become compromised on the pan-retinal level, which is reflected by the appearance of full-field ERG abnormalities



Vision Research 12/2003

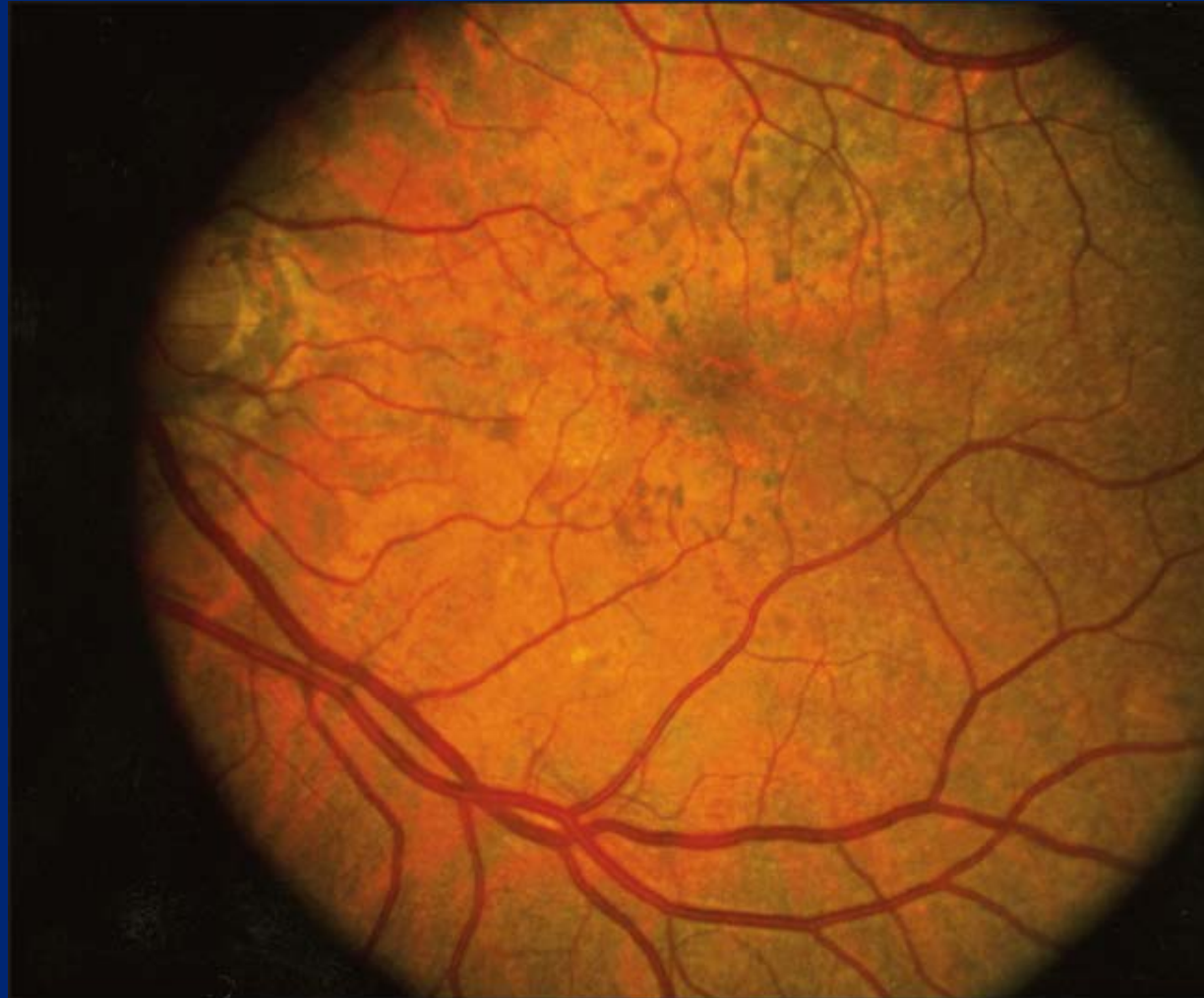Fundus Pulverulentus

Probably the rarest type of all pattern dystrophies

First described by Slezak in 1969 and is characterized by coarse pigment mottling of the pigment epithelium in the macular area

Sometimes pigmentary changes are difficult to differentiate from the ones seen in many other maculopathies, including AMD

Fluorescein angiography usually shows hypofluorescent spots corresponding to the pigment mottling



Treatment

- Patients diagnosed with AVMD should be frequently evaluated with an Amsler grid to elucidate changes or decreases in vision that may represent formation of CNV
- As this is a genetic disorder, family members should be examined and there is genetic testing available
- Some case reports indicate that anti-VEGF is effective against choroidal neovascularization, but to date there are no clinically established treatments available
- Rationale for treating with anti-VEGF is to stabilize the outer blood–retinal barrier and restore apposition between the photoreceptor outer segment tips and the apical surface of the retinal pigment epithelium, thus reducing subretinal fluid
- Restoring normal outer segment turnover, allowing the elimination of the non-cellular components of the vitelliform detachment

Back to our Patient

- ⦿ **Patient educated about her diagnosis of Acquired Vitelliform Macular Dystrophy**
- ⦿ **Was informed that a likely cause of her decreased vision in her 50's could be attributed to the nature of her disease**
- ⦿ **Pt was given a home amsler grid and told to come back immediately prn any changes**
- ⦿ **Encouraged to get her family members tested and be seen given autosomal dominant nature of disease**

Reflective Practice

This case demonstrated the importance of a thorough ophthalmic exam and diagnostic workup and allowed me to learn more about a rare disease entity and its complications.

It also allowed me to evaluate the literature for the differential diagnoses of this disease entity while keeping in mind my patient's expectations.

Core Competencies

Patient Care: The case involved thorough patient care and careful attention to the patient's past medical history. Once diagnosed, the patient received proper management and follow up care with the retinal service.

Medical Knowledge: This presentation allowed me to review the presentation, differential diagnosis, proper evaluation/work up, and different treatment options for Acquired Vitelliform Macular Dystrophy.

Practice-Based Learning and Improvement: This presentation included a current literature search of current treatment modalities for Acquired Vitelliform Macular Dystrophy.

Interpersonal and Communication Skills: The patient was treated with respect and every effort was made to communicate with the patient in a timely manner.

Professionalism: The patient was diagnosed in a timely manner. She was informed of her diagnosis and explained current treatment options.

Systems-Based Practice: The patient was discussed with the retina service about the prognosis and best treatment options available.

References:

1. **W Saito, et al.** Morphological and Functional Analyses of Adult Onset Vitelliform Macular Dystrophy. *Br J Ophthalmol.* 2003 June; 87(6): 758–762
2. **Kay DB, Land ME, Cooper RF, et al.** Outer Retinal Structure in Best Vitelliform Macular Dystrophy. *JAMA Ophthalmol.* 2013;():1-9
3. **Mimoun, G et al.** Ranibizumab for Choroidal Neovascularization Associated with Adult-onset Foveomacular Vitelliform Dystrophy: one-year results. *Retina* 2013 Mar;33(3):513-21
4. **Zhang, Q, Small, K, Grossniklaus, H Bilyk JR.** Clinicopathologic findings in Best vitelliform macular dystrophy. *Graefes Arch Clin Exp Ophthalmol.* 2011 May ; 249(5): 745–751
5. **Dubovy SR, Hairston RJ, Schatz H, Schachat AP, Bressler NM, Finkelstein D et al.** Adult-onset foveomacular pigment epithelial dystrophy. Clinicopathologic correlation of three cases. *Retina* 2000, 20: 638–649
6. **JJ Arnold, JP Sarks, MC Killingsworth, EK Kettle S H Sarks.** Adult vitelliform macular degeneration: a clinicopathological study. *Eye* (2003) 17, 717–726

Thank you

- ⦿ Patient
- ⦿ Dr. Glatman

